
بسم الله الرحمن الرحيم

Hints in

HEPATIC DOPPLER

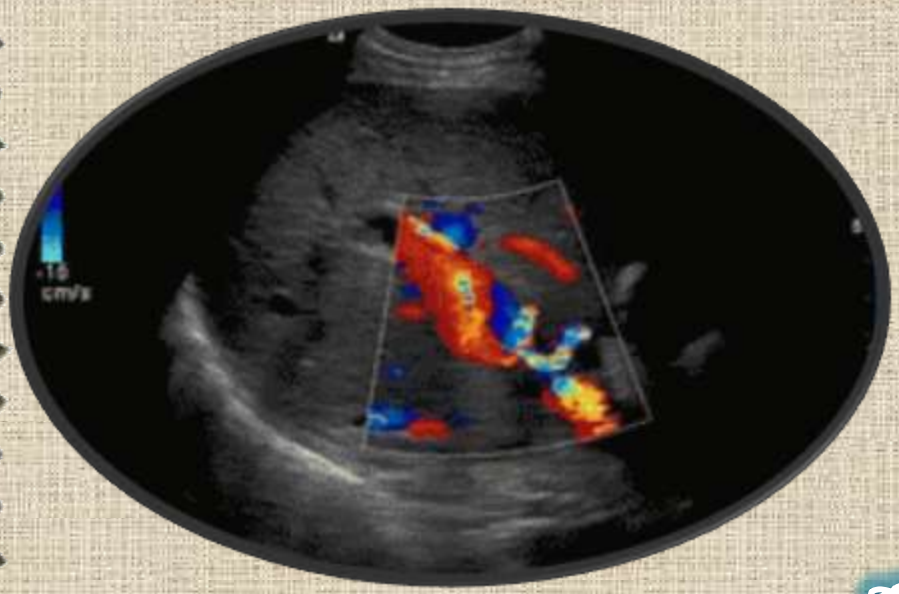

By

Ahmad Mokhtar Abodahab

Ass. Lecturer of Radio diagnosis

Sohag University

- The portal venous system drains:
  - GIT,
  - pancreas,
  - spleen, and
  - biliary tree.
- Itempties via the main portal vein,
- which supplies 70% of the blood flow to the liver.

- Blood supply of the liver “70% PV – 30% Hepatic A.” → Hepatic sinusoids → central vein of every lobules → Hepatic Veins → IVC


PORTAL

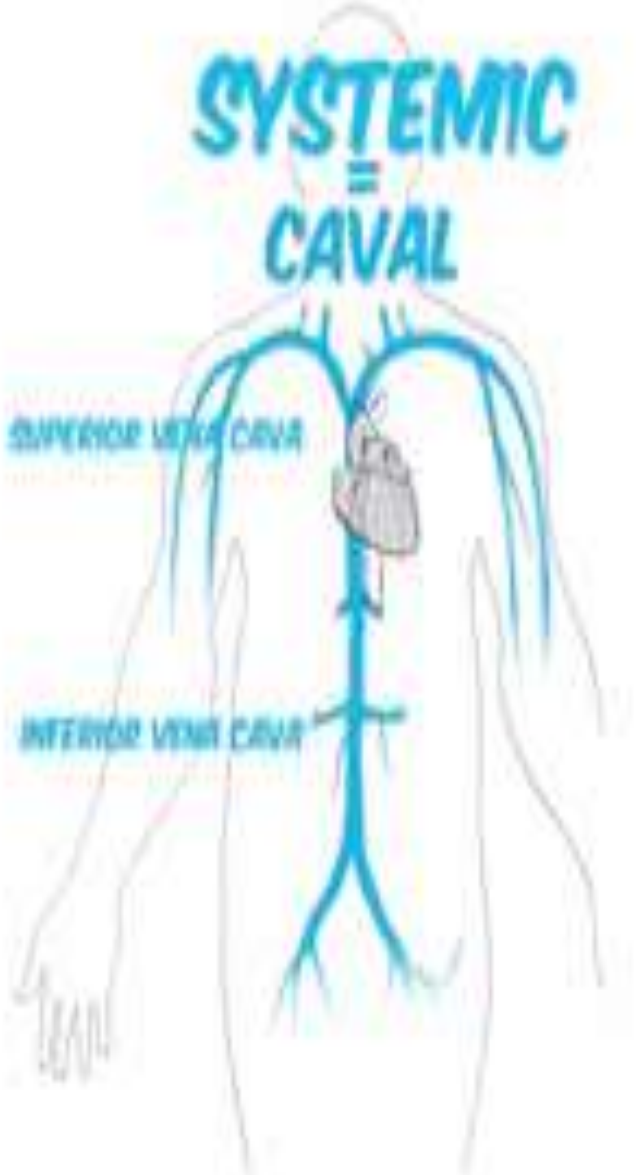
SYSTEMIC
=
CAVAL
SUPERIOR VENA CAVA
INFERIOR VENA CAVA

- main Portal Vein is formed by :

the union of

  - superior mesenteric and
  - splenic vein.

- Normal PV pressure < 10 mmHg

Portal Hypertension

- PV pressure > 10 mm Hg
- Causes :

* *Pre Hepatic* * *Hepatic* * *Post Hepatic*

- it is usually a sequel of ***chronic liver disease***,
- but can occur in ***fulminant liver failure***.

Table 7. Causes of portal hypertension:	Varicositas	Ascites
Prehepatic causes:	often	rare
➢ thrombosis of portal vein ➢ external compression of portal vein - tumor - enlarged lymph nodes		
Intrahepatic causes:	often	rare
➢ narrowing/obstruction of blood flow in the liver - alcoholic chirrosis – structural remodeling in liver fibrosis		
Posthepatic causes:	often	often
➢ thrombosis of hepatic veins ➢ venoocclusive diseases ➢ severe right-sided heart failure ➢ Budd-Chiari syndrome - congenital occlusion of portal vein		

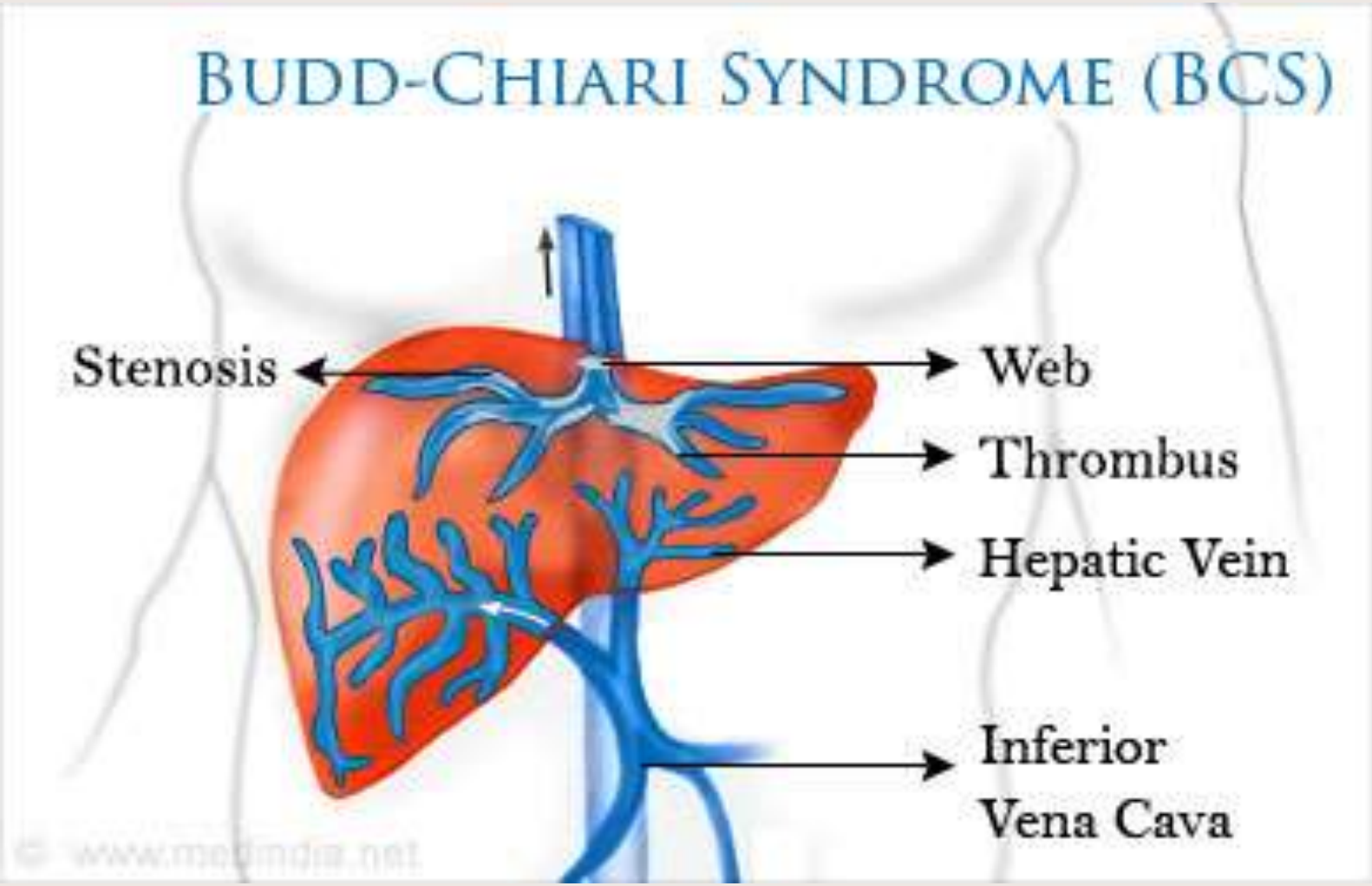

- = Hepatic venous outflow obstruction

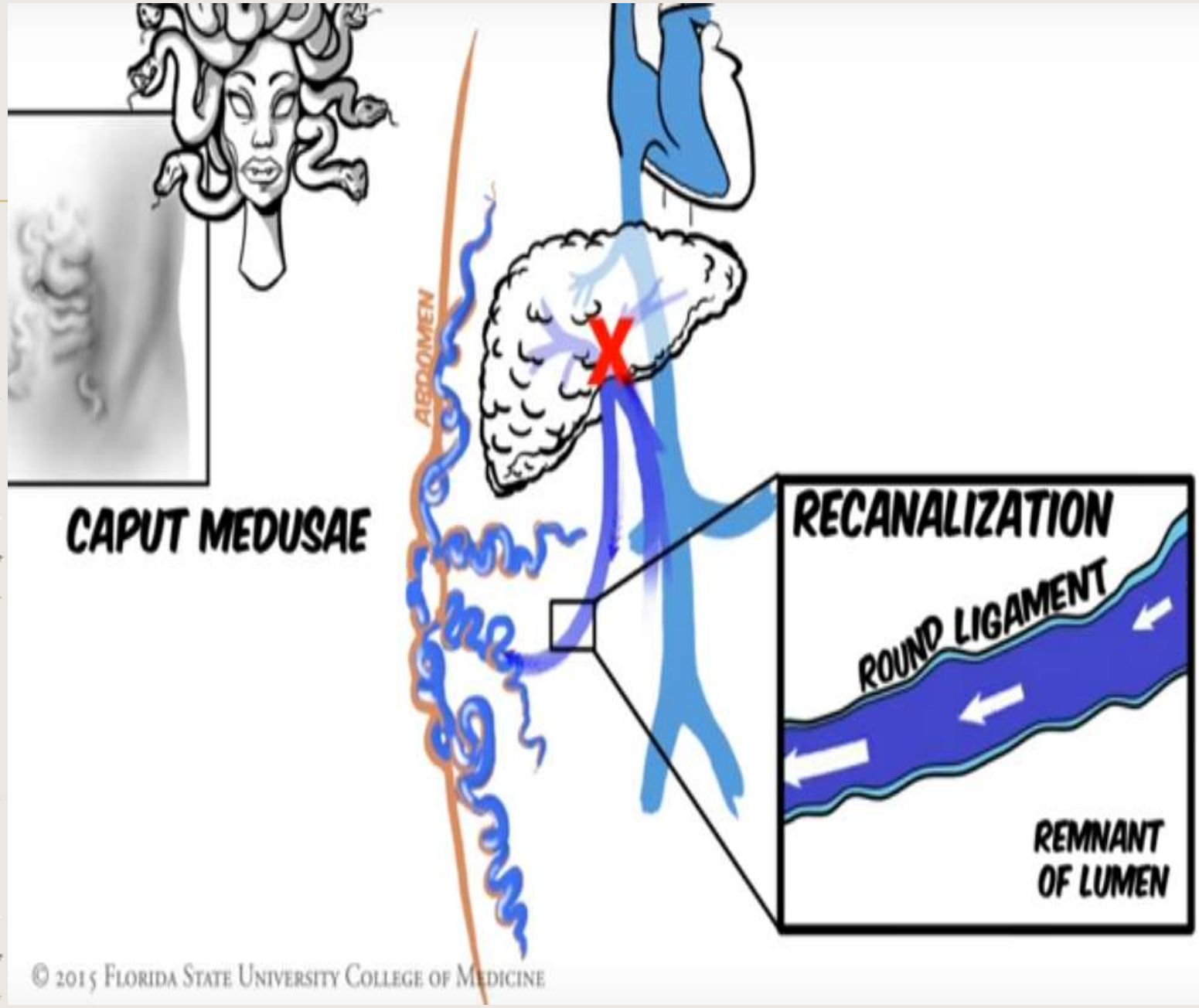
CAPUT MEDUSAE
ABDOMEN
X
RECANALIZATION
ROUND LIGAMENT
REMNANT
OF LUMEN
© 2015 Florida State University College of Medicine

ANORECTAL VARICES

HEMORRHOIDS

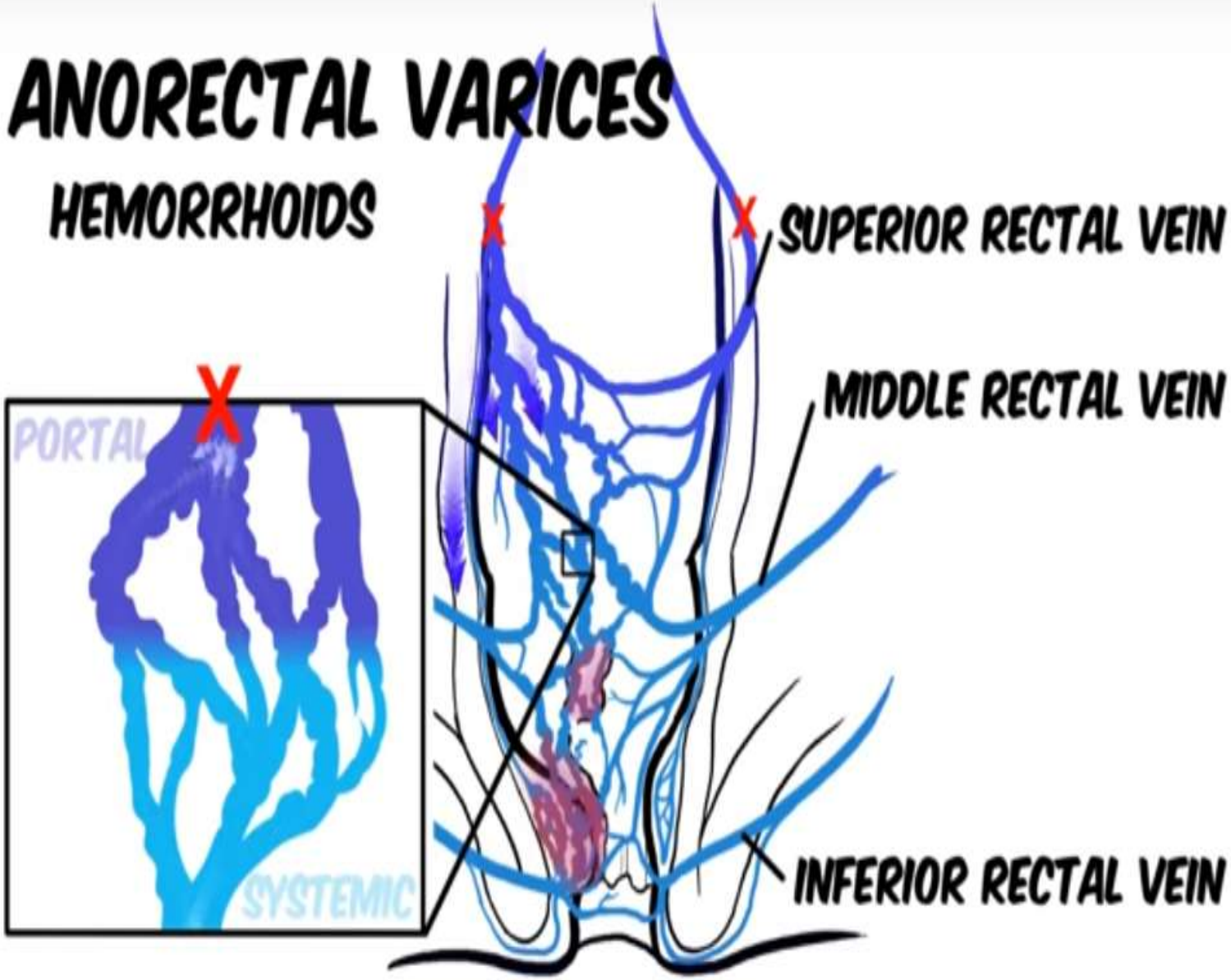

PORTAL HYPERTENSION

The Florida State University
College of Medicine

PORTAL

PORTOSYSTEMIC ANASTOMOSIS

SYSTEMIC
CAVAL

PRESSURE

PORTAL PRESSURE

CAVAL PRESSURE

BLOOD PRESSURE

VARICES

ESOPHAGEAL VARICES

BLOOD BLACK, TARRY STOOL

BREAKDOWN OF RED BLOOD CELLS

POTENTIALLY LETHAL

ANORECTAL VARICES

HEMORRHOIDS

SUPERIOR RECTAL VEIN

MIDDLE RECTAL VEIN

INFERIOR RECTAL VEIN

SURGICAL REPAIR

PORTAL VEIN TO IVC

SPLENIC VEIN TO RENAL VEIN

CAPUT MEDUSAE

"MEDUSA'S HEAD"

FETAL DEVELOPMENT

MICROSURGERY

TRANSJUGULAR INTRAHEPATIC PORTOSYSTEMIC SHUNTING

TIPS

Three basic levels of US should be performed :

- **1st level**: gray-scale US (B-mode imaging).
- **2nd level**: color Doppler examination (produces an image that shows blood flow in vessels).
- **3rd level:** spectral Doppler examination (over a vessel of interest, produces a spectral
- Doppler waveform).

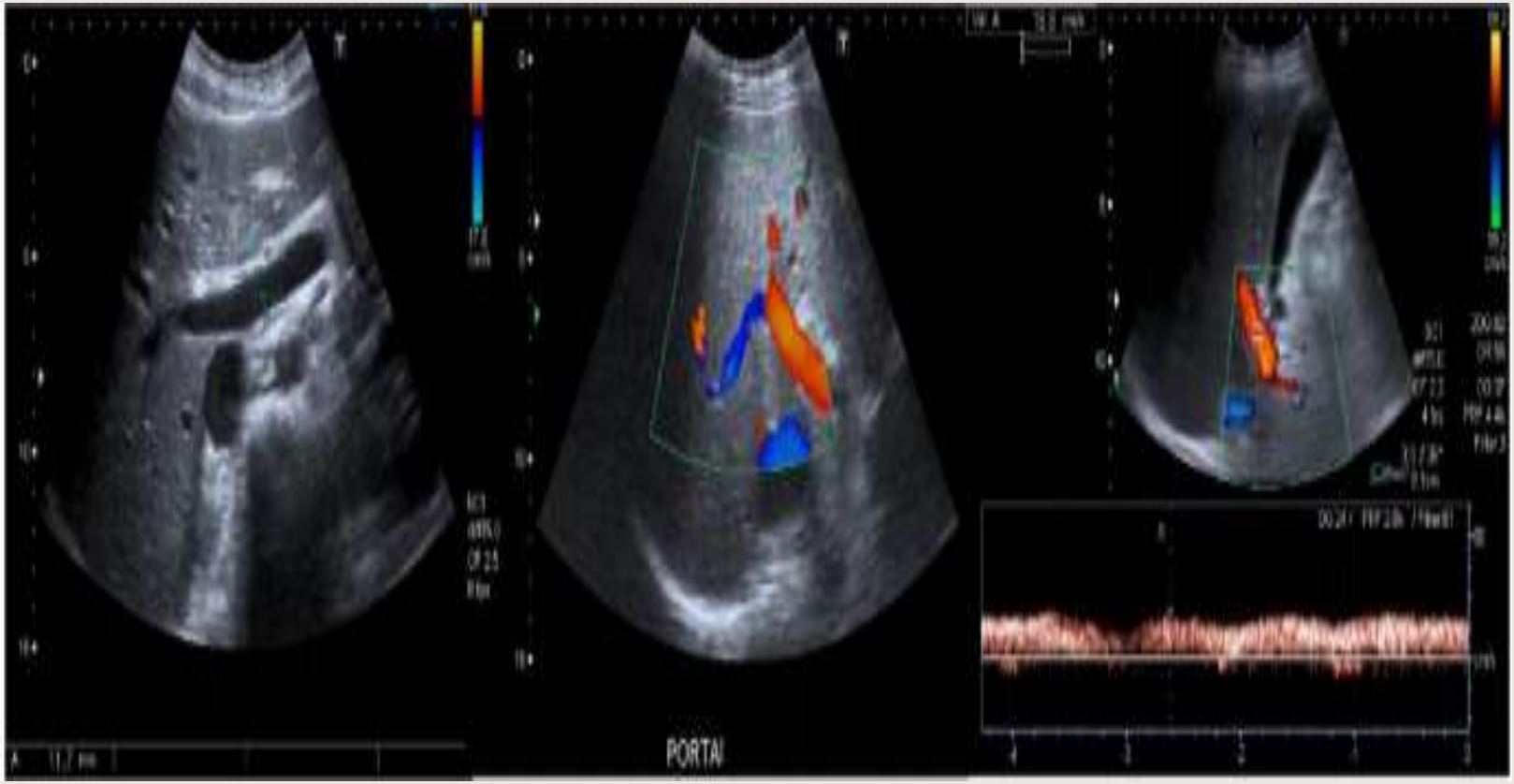
PORTAl

Targets of Doppler Ex.

- PV "the main target"
  - Hepatic Veins
    - Hepatic A.
    - IVC

1- P.V.

US VIEW OF PV

- Many views , …but the best Rt inter costal

* Normal portal vein is *less than 13 mm*


05/27/10
10:14:45 AM
Ab/Easy
P4-1/CH4MHz
DR65/M3/P2
G80/E1/100%
MI1.3 TIs0.5
16.0 cm
ZSI 0
MPV

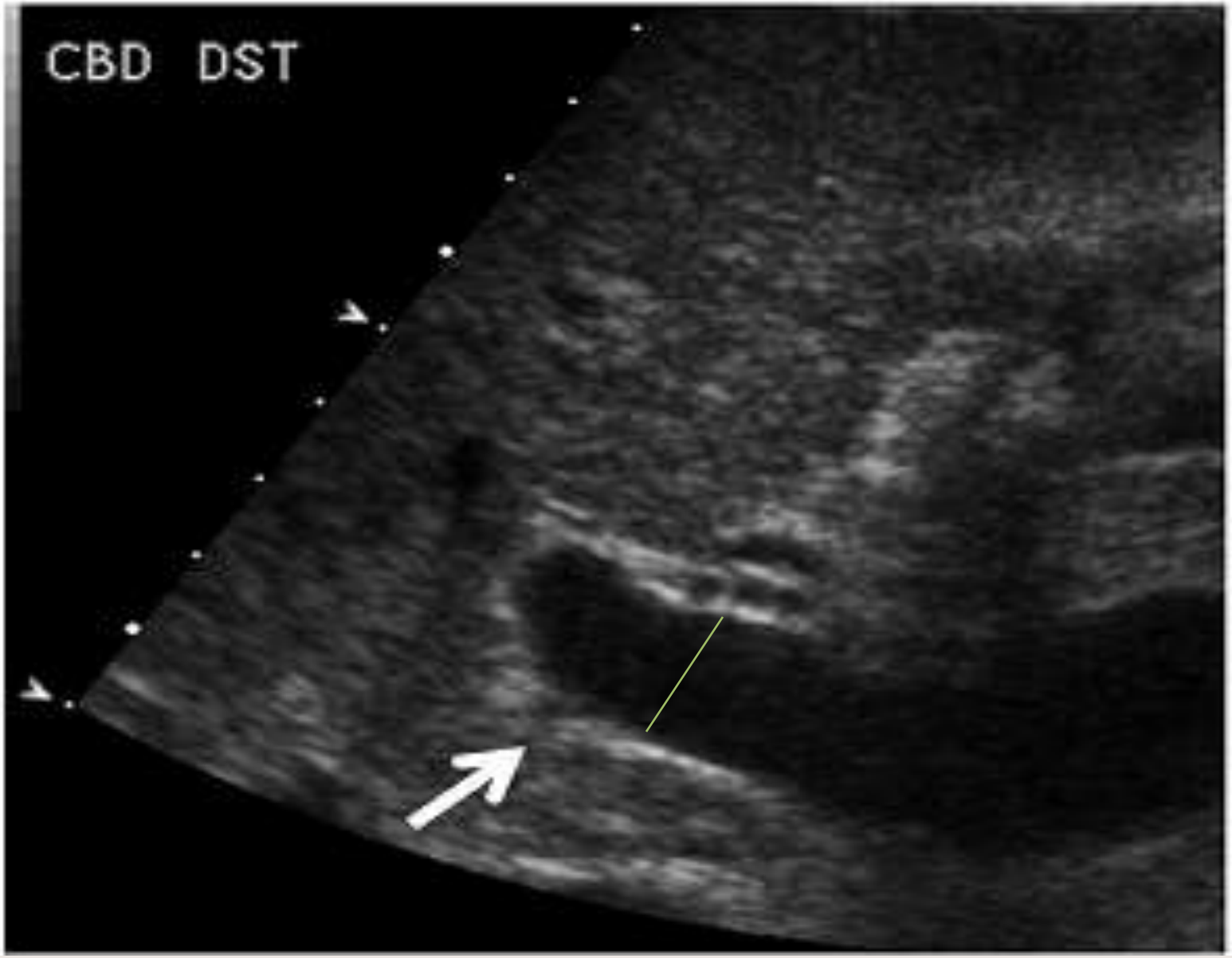
CBD DST


A-Abdomen
imgflip.com

PV Gases

- Portal venous gas is associated with :
  - Bowel ischemia,
  - inflammation (including appendicitis and diverticulitis),
  - & sepsis.
- It is also seen in benign conditions, such as :
  - intestinal pneumatosis or
  - after endoscopy.
- **Gas appears as intraluminal strongly echogenic foci that move with the blood**


LOGIQ
E9
2
4
6
imgflip.com
LIVER TRANS

1- PORTAL VEIN

To evaluate:

- Color Filling
- Wave form
- Velocity
- Doppler indices

1- PV flow color

- Toward the liver


16
-16
cm/s
imgflip.com

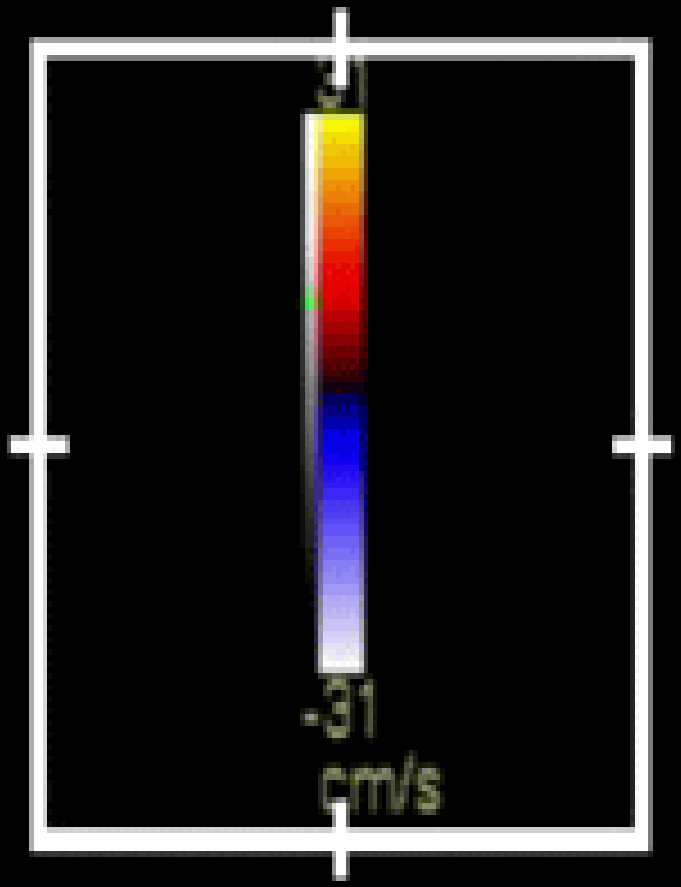

How to determine flow direction?

Flow Toward Probe

Flow Away Probe

BOTH PV & HEPATIC A. HAS FLOW TOWARD THE LIVER

- PV Direction flow can be altered from normal → To liver

To Abnormal …as away from liver , or Bidirectional

* WHILE **HEPATIC A.** HAS ONLY ONE FLOW PATTERN TOWARD LIVER IN ALL CIRCUMSTANCES.

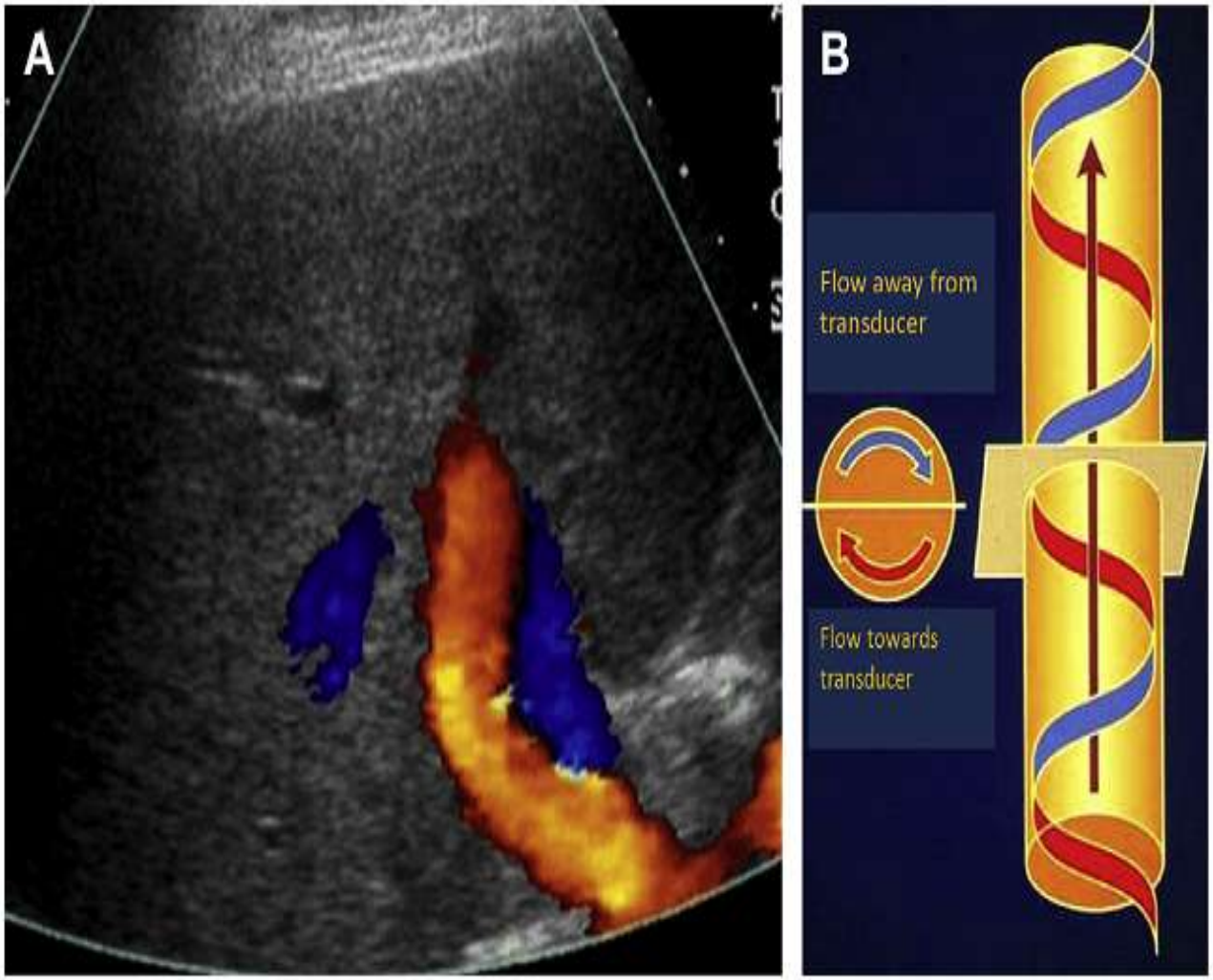

Fig. 5. (*A*) Color Doppler of helical portal venous flow at the hepatic hilum. Flow is antegrade, but appears as alternating red and blue spiral bands (*B*). This appearance should not be confused with hepatofugal flow.

BIDIRECTIONAL

•Hepatopetal portal vein flow, shown in blue indicative of the ***most severe stage of portal hypertension.***

•It is also seen in *Fulminant hepatic failure*.

•The multicolored vessel (arrow) superficial to the portal vein is the hepatic artery.

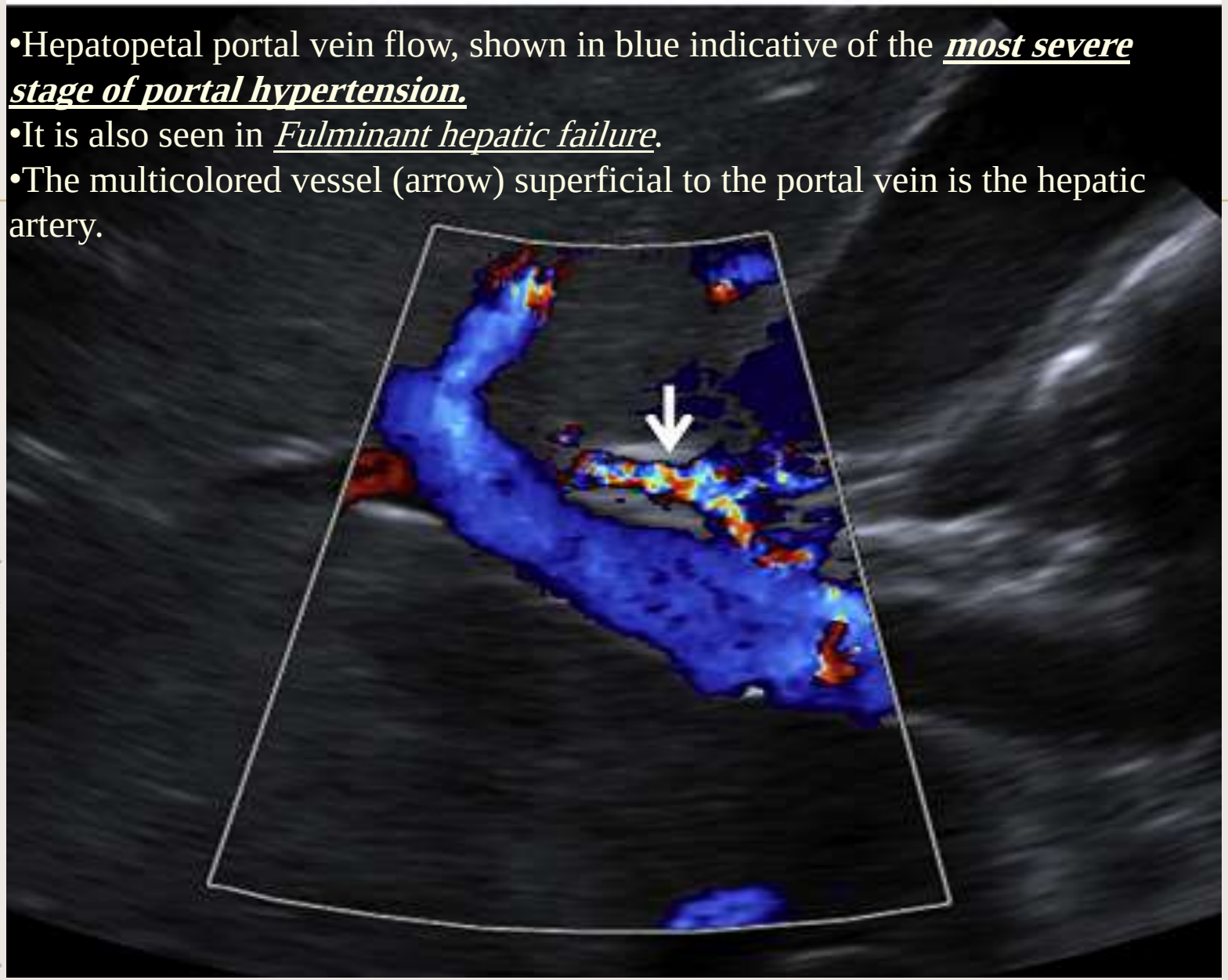

2-Portal vein wave form

- Continuous waveform , with respiratory modulation


A-Abdomen
imgflip.com

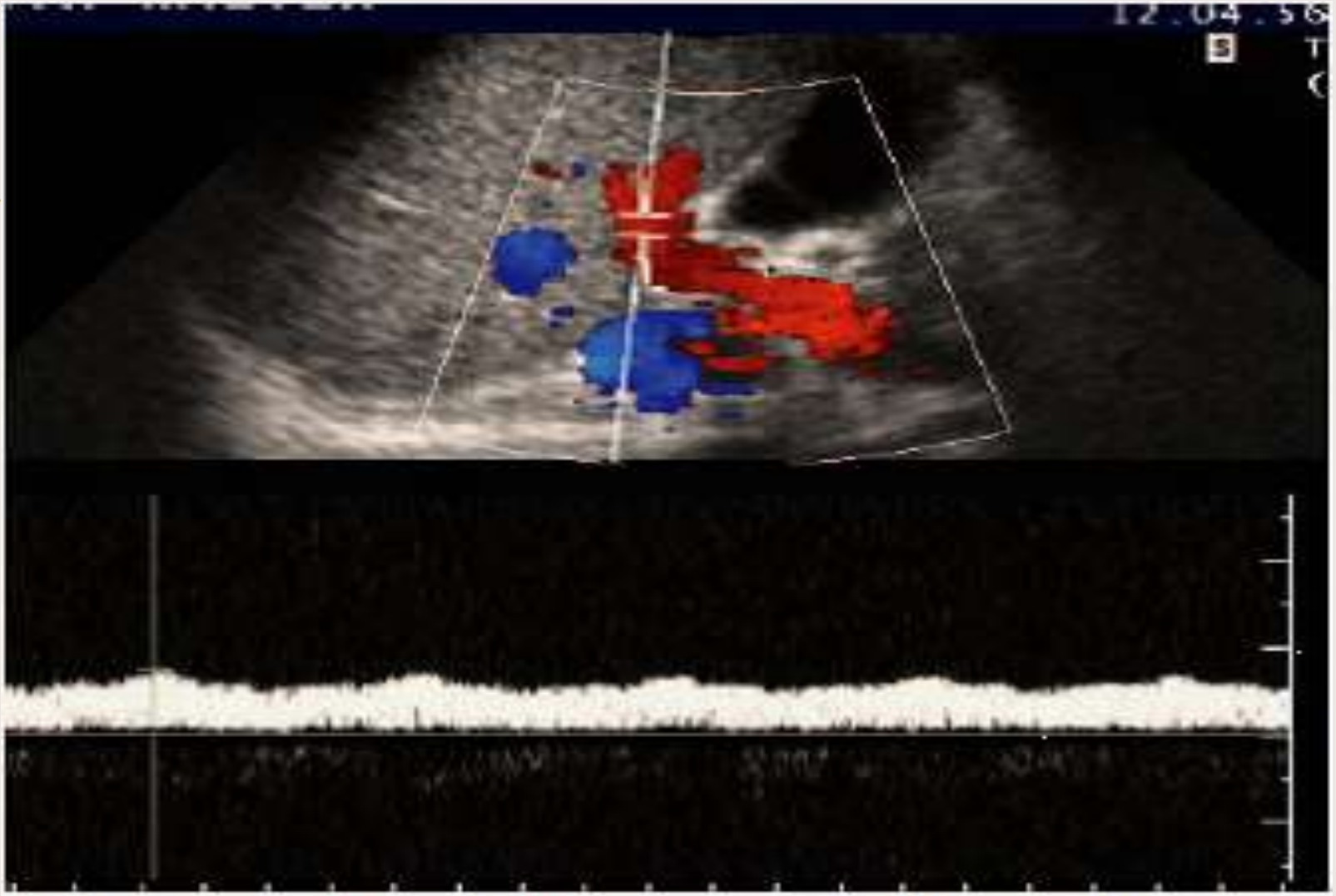

Figure 2.26 Normal portal vein waveform. Respiratory modulations are evident.


A-Abdomen
imgflip.com

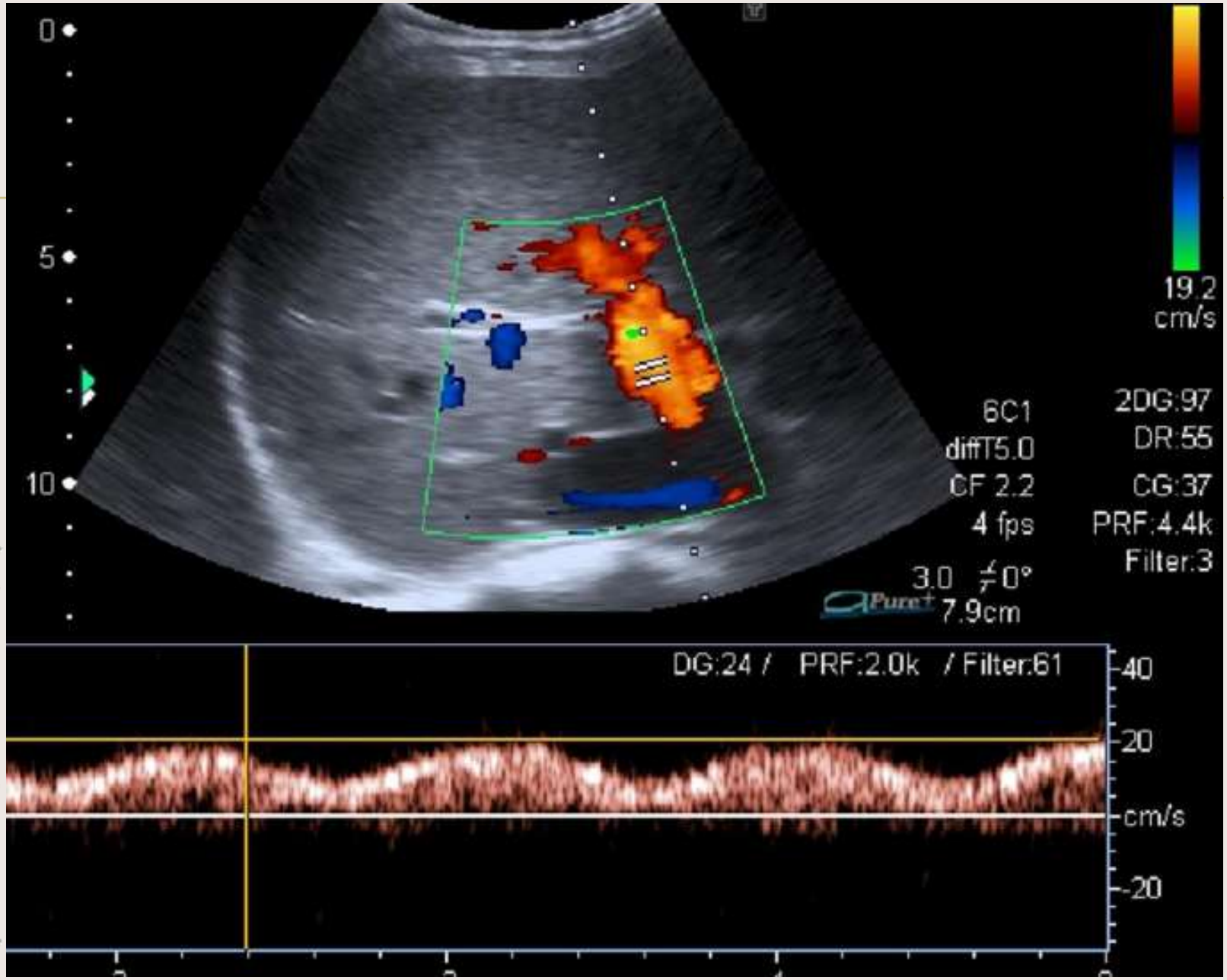
0
5
10
19.2
cm/s
6C1
diffT5.0
CF 2.2
4 fps
3.0 ∠0°
7.9cm
2DG:97
DR:55
CG:37
PRF:4.4k
Filter:3
DG:24 / PRF:2.0k / Filter:61
40
20
cm/s
-20

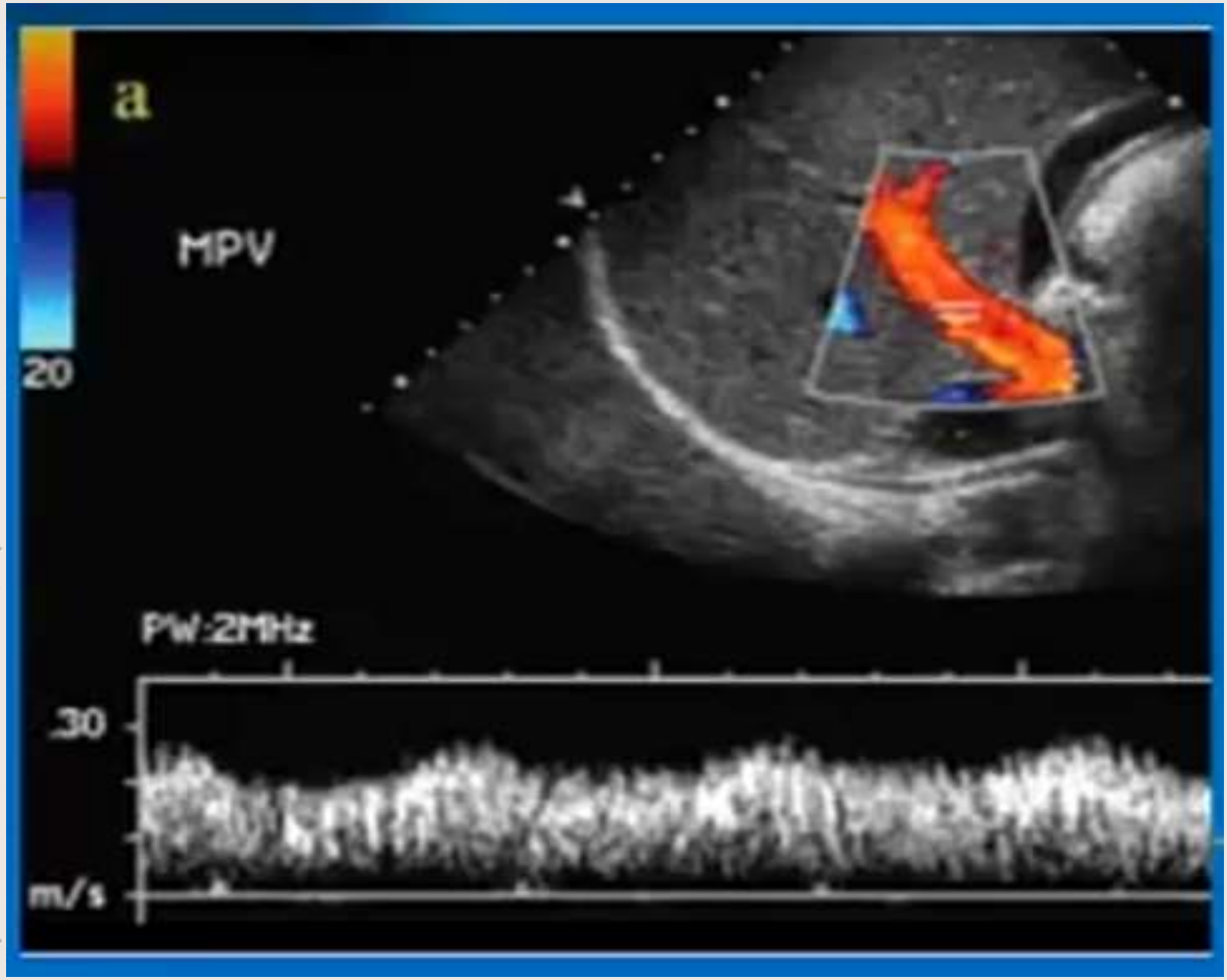
a
MPV
20
PW:2MHz
30
m/s

Bidirectional Flow

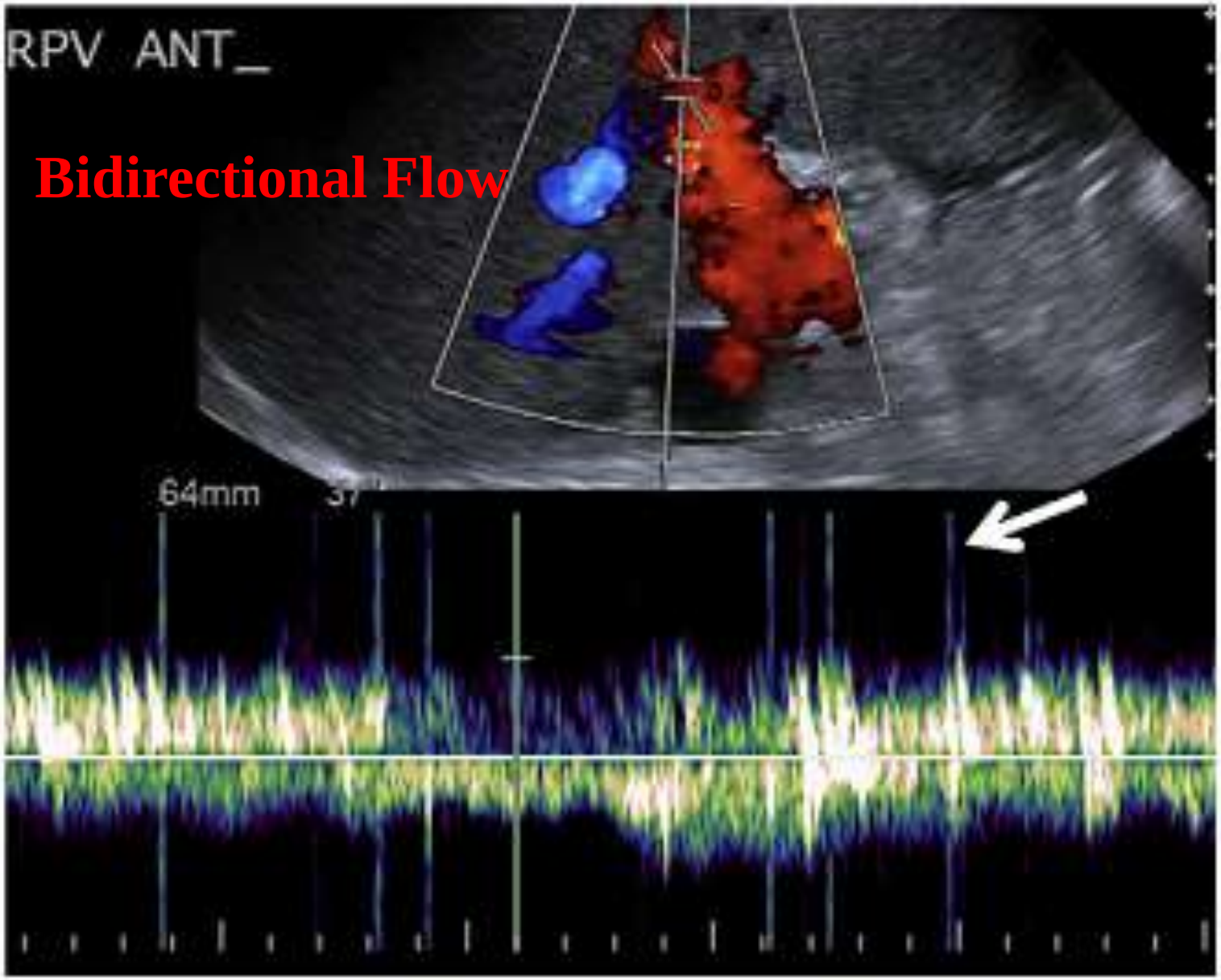

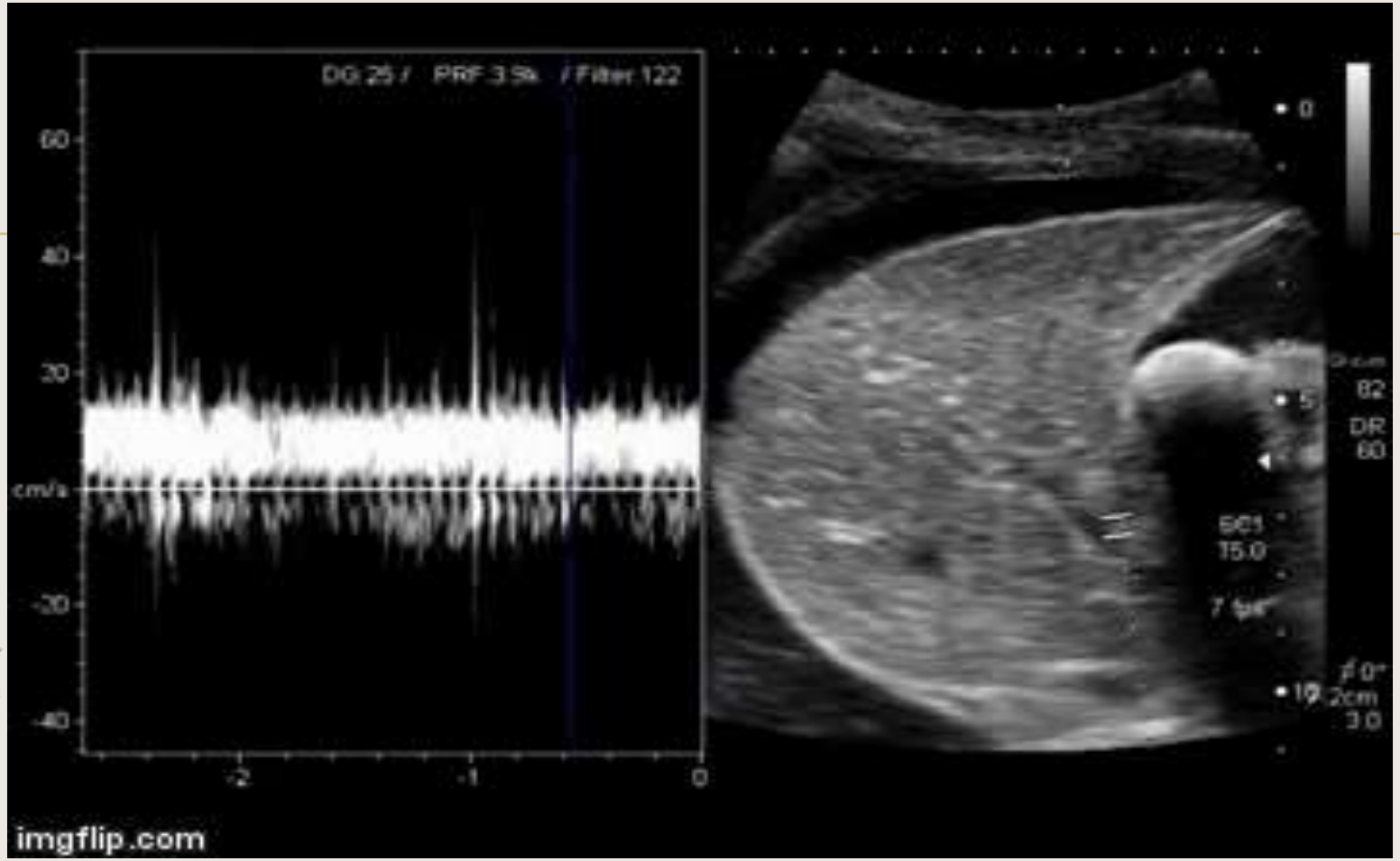

- GAS in PV generates a characteristic ***<u>"spiky" artifact</u>*** on the Doppler spectrum consisting of intermittent strong signals that extend over the baseline, superimposed on the normal venous waveform.

3- PV velocity

- Normal portal vein flow is *hepatopetal,*

"TO THE LIVER"

- Normal velocity 20 : 33 cm/ sec
- flow is
  - Never retrograde
  - increases postprandially
  - in the supine position
- cirrhosis 11 cm / sec

Congestional index

- = Cross section Daimeter / Flow Velocity
- in Portal Hypertension :
  - Diameter increased
  - Velocity decreased
- Thus C.I. in Potal hypertension > Normal



Normal Congistional Index	0.06
Portal Hypertension	0.11
Esophageal varices	0.14

PORTAL VEIN STENOSIS

- **Causes** :
  - Pancreatic enlargement by :
    - tumor or inflammation encroaching on the vein,
  - postsurgical stenosis,
  - Anastomotic stenosis in a patient after transplantation.
- Doppler findings in portal vein stenosis include :
  - Poststenotic *dilatation* on gray-scale ultra-sound.
  - *Turbulent,* poststenotic flow on color Doppler imaging
  - Spectral Doppler imaging shows *elevated peak systolic velocity*

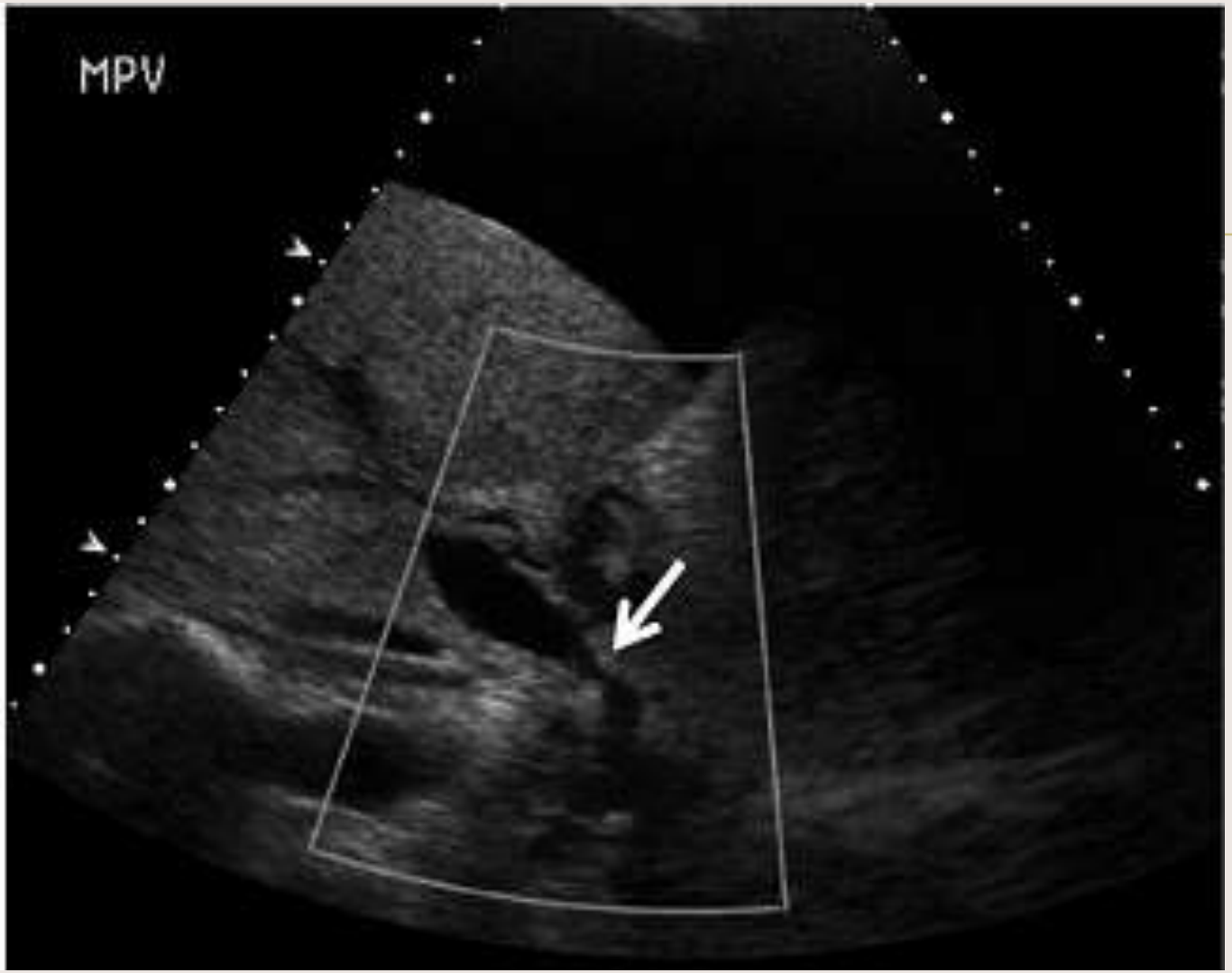

- Gray-scale ultrasound demonstrates focal stenosis in the portal vein (arrow) and post stenotic dilata-tion.

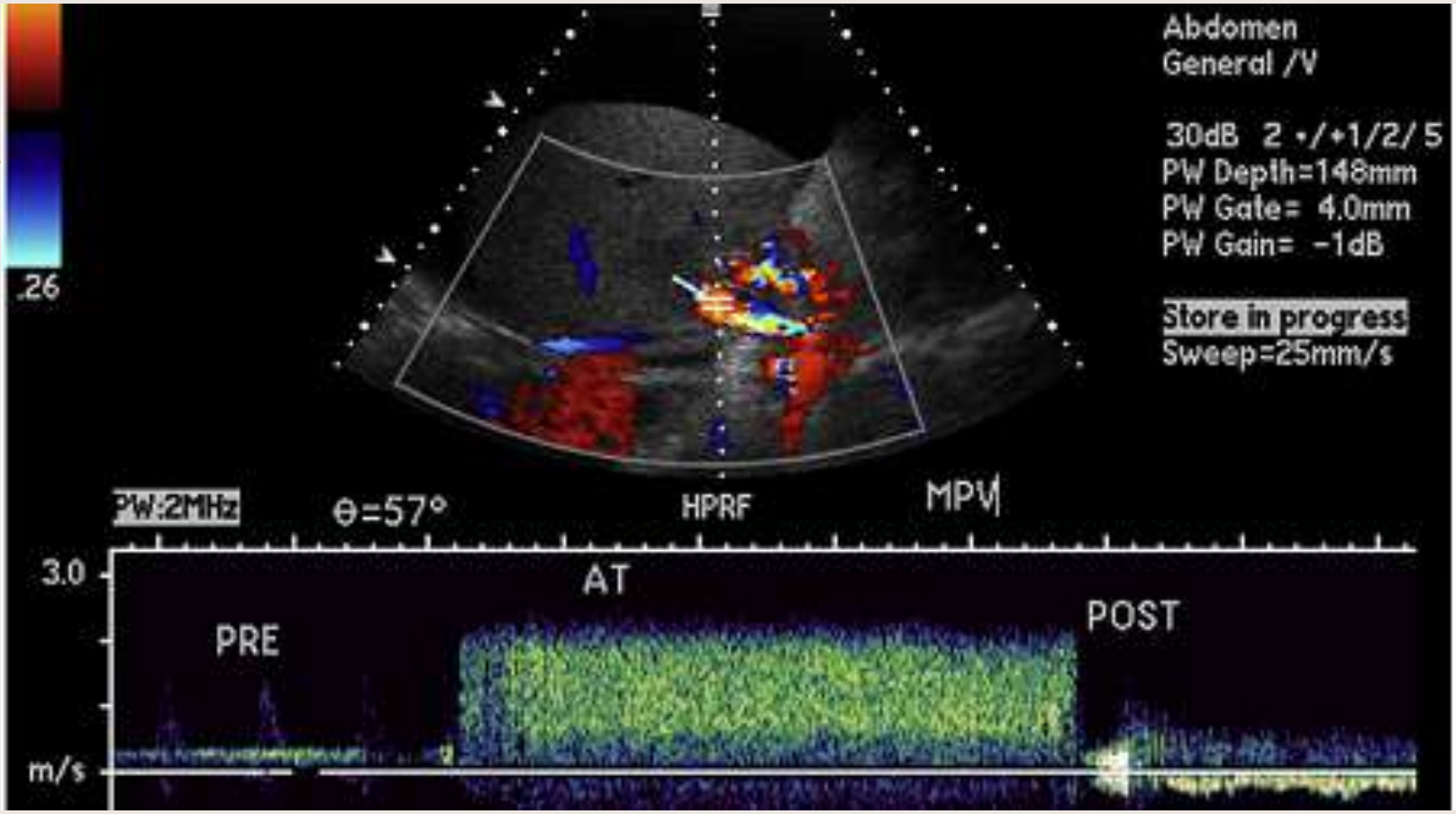

Spectral Doppler imaging demonstrates
a velocity step-up of greater than 3:1
when comparing post-stenosis with prestenosis velocity.

PORTAL VEIN THROMBOSIS

- Causes :
  - Stagnant flow
  - **Neoplasms** : such as pancreatic carcinoma and cholangiocarcinoma.
  - hepatocellular carcinoma (HCC) : is unusual.
  - **Inflammation**: acute pancreatitis or diverticulitis,
  - **Hypercoagulable states** : dehydration, pro-thrombotic states, myoproliferative disorders, and *oral contraceptive pill*.

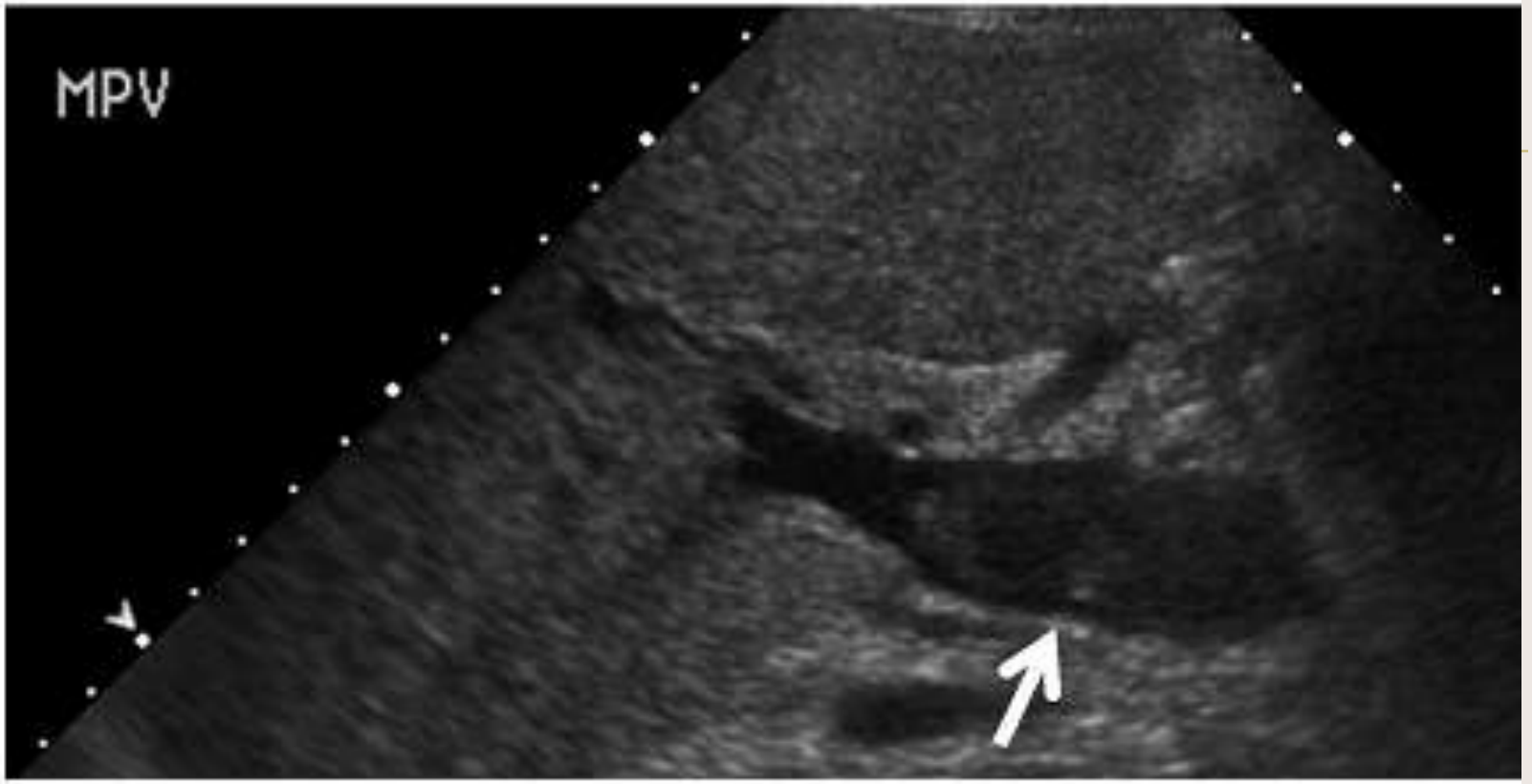

- Visible thrombus (arrow) in the portal vein on a gray-scale image in the main portal vein.

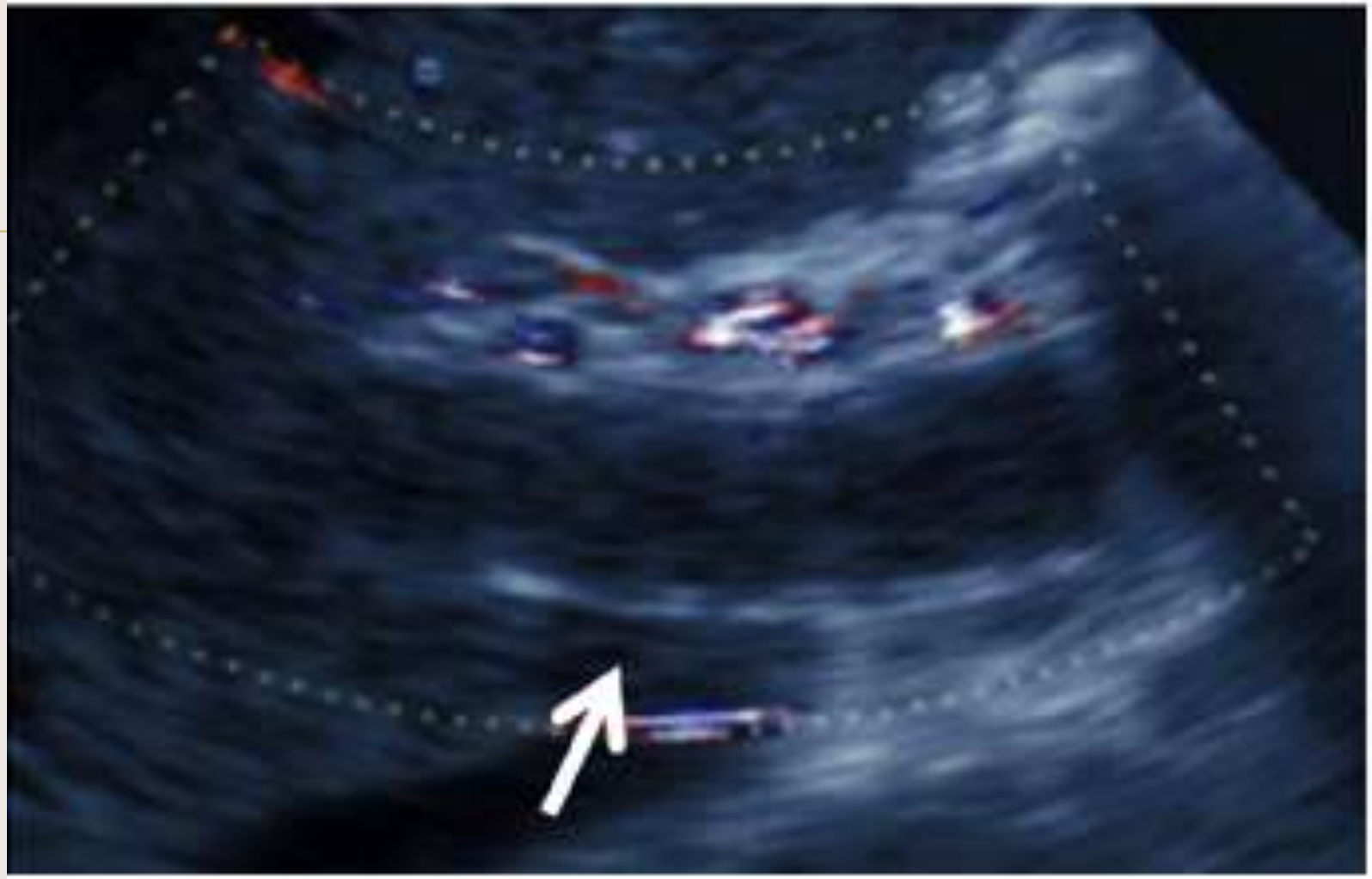

- **Acute thrombus** is more common to be anechoic. In this patient, it is only visible as absence of flow on color Doppler (arrow). Flow is seen in the hepatic artery superficial to the portal vein.

echogenic material within the portal vein lumen (slightly dilated)

* Absence of portal flow on color Doppler examination

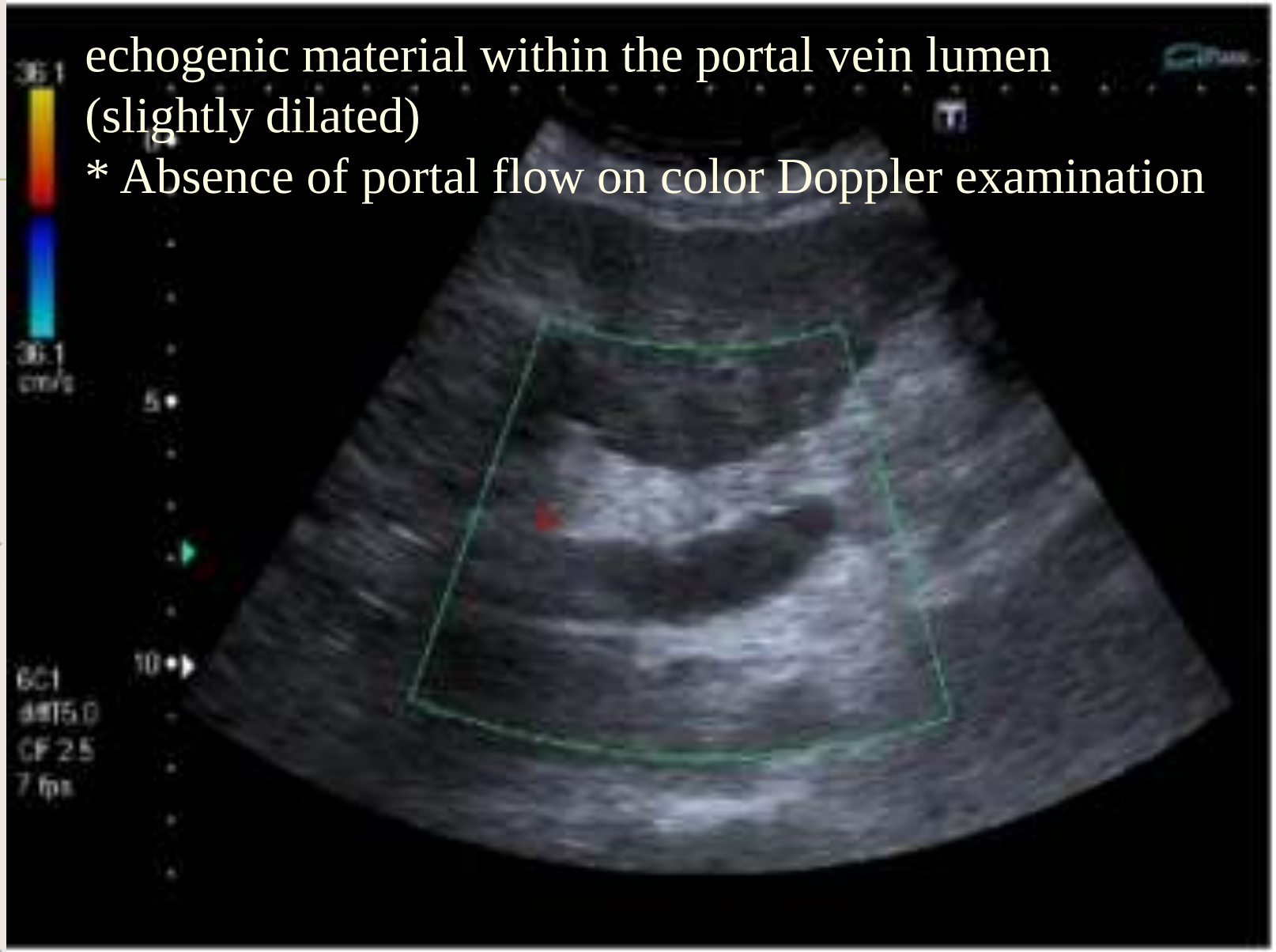

Fig. 13. In chronic portal vein thrombosis, the portal vein wall is thickened and the lumen (marked by calipers) is narrowed.

Sonographic features of portal hypertension

- Initially → slow (<20 cm/s) hepatopetal flow .
- Enlarged PV greater than 1.3 cm
- **Splenomegaly:** >12 cm longitudi-nal diameter
- Ascites
- **Varices**: gastroesophageal, splenic
- **Portosystemic collaterals**:
  - recanalized umbilical vein.
  - Monophasic waveforms in the **hepatic veins**
  - Increased resistive index in **hepatic** and **splenic arteries**

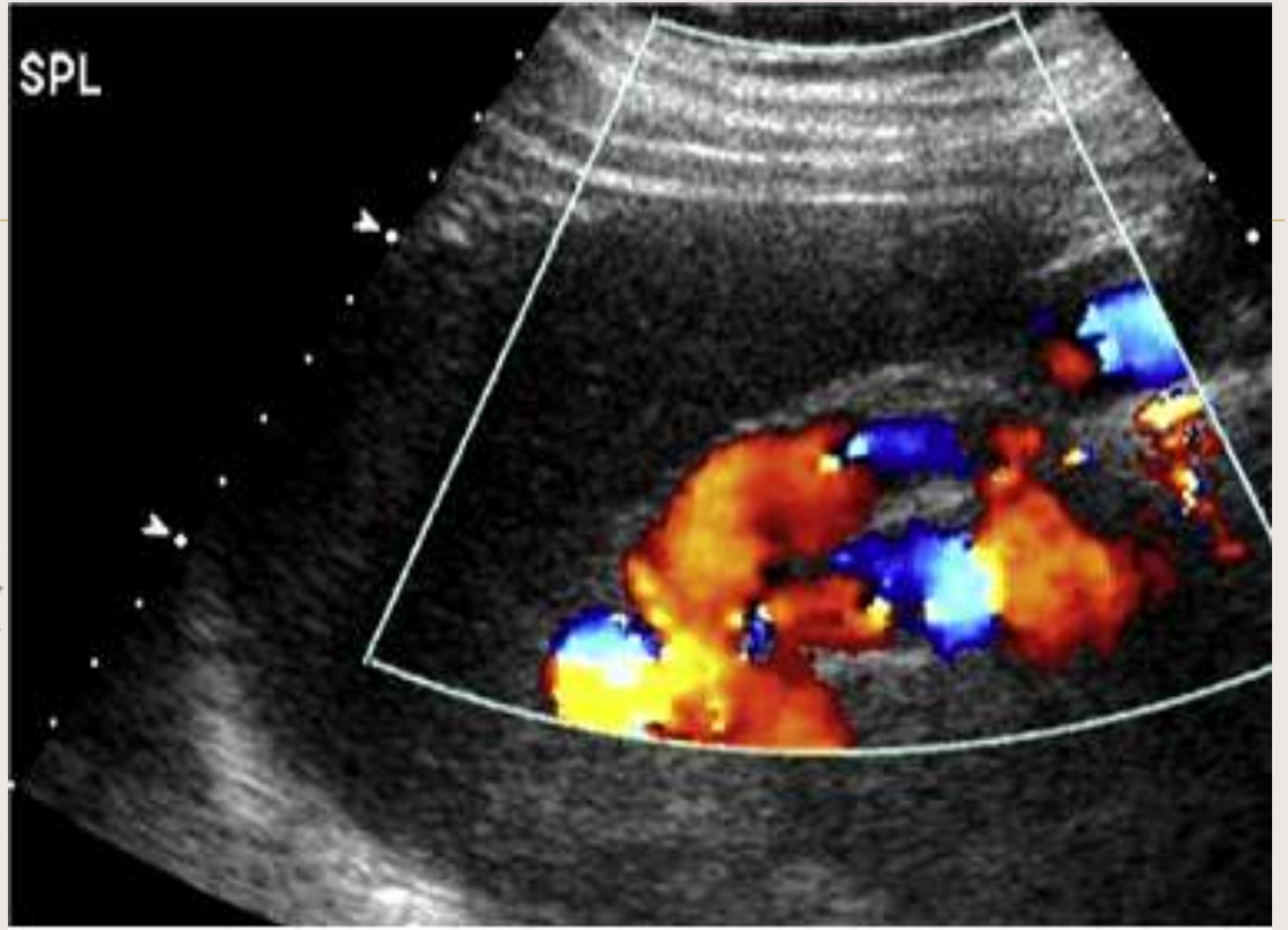

Longitu-dinal view of spleen showing varices at the splenic hilum.

2- HEPATIC VEINS

- 3 main hepatic veins
- (right, middle, and left),
- converge onto the IVC on the posterior surface of the liver
- common variant : middle and left hepatic veins join before draining, as a common trunk, into the IVC.

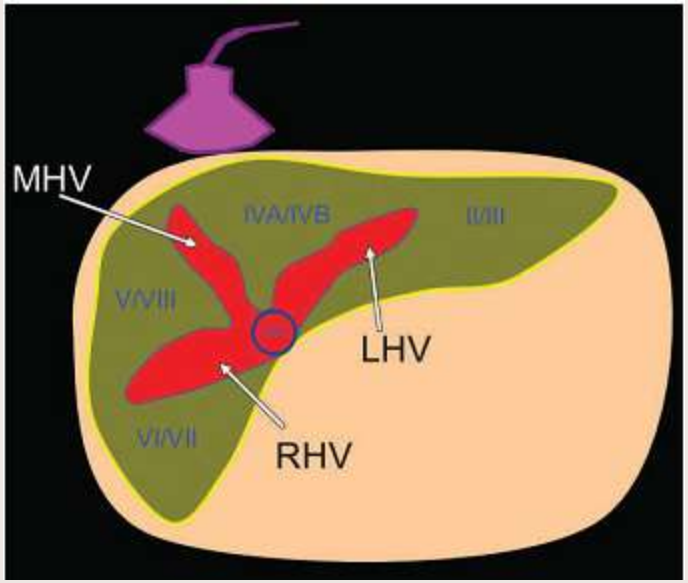

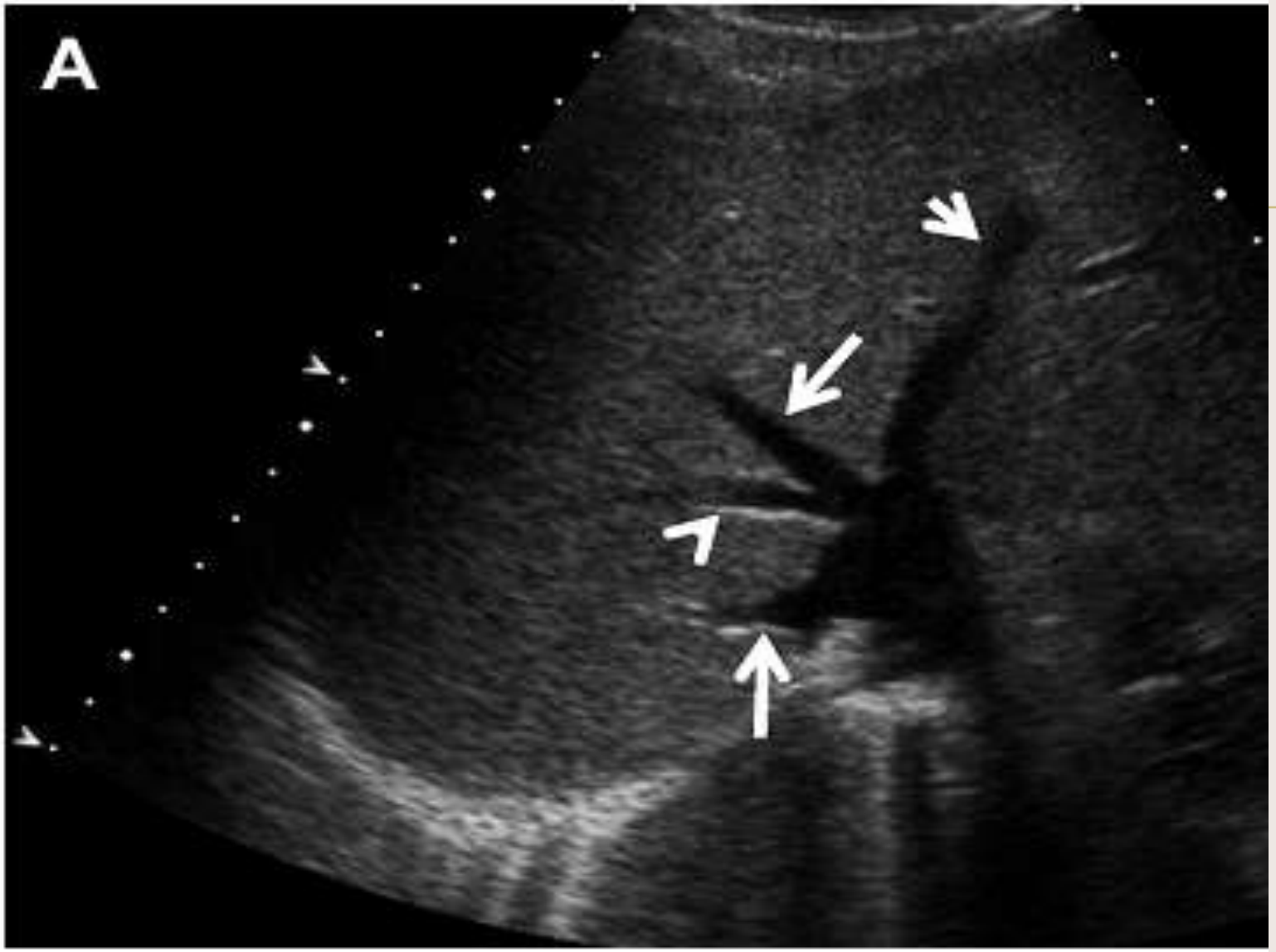

- An accessory vein (arrowheads) empties into the IVC at its junction
- with the middle hepatic vein.

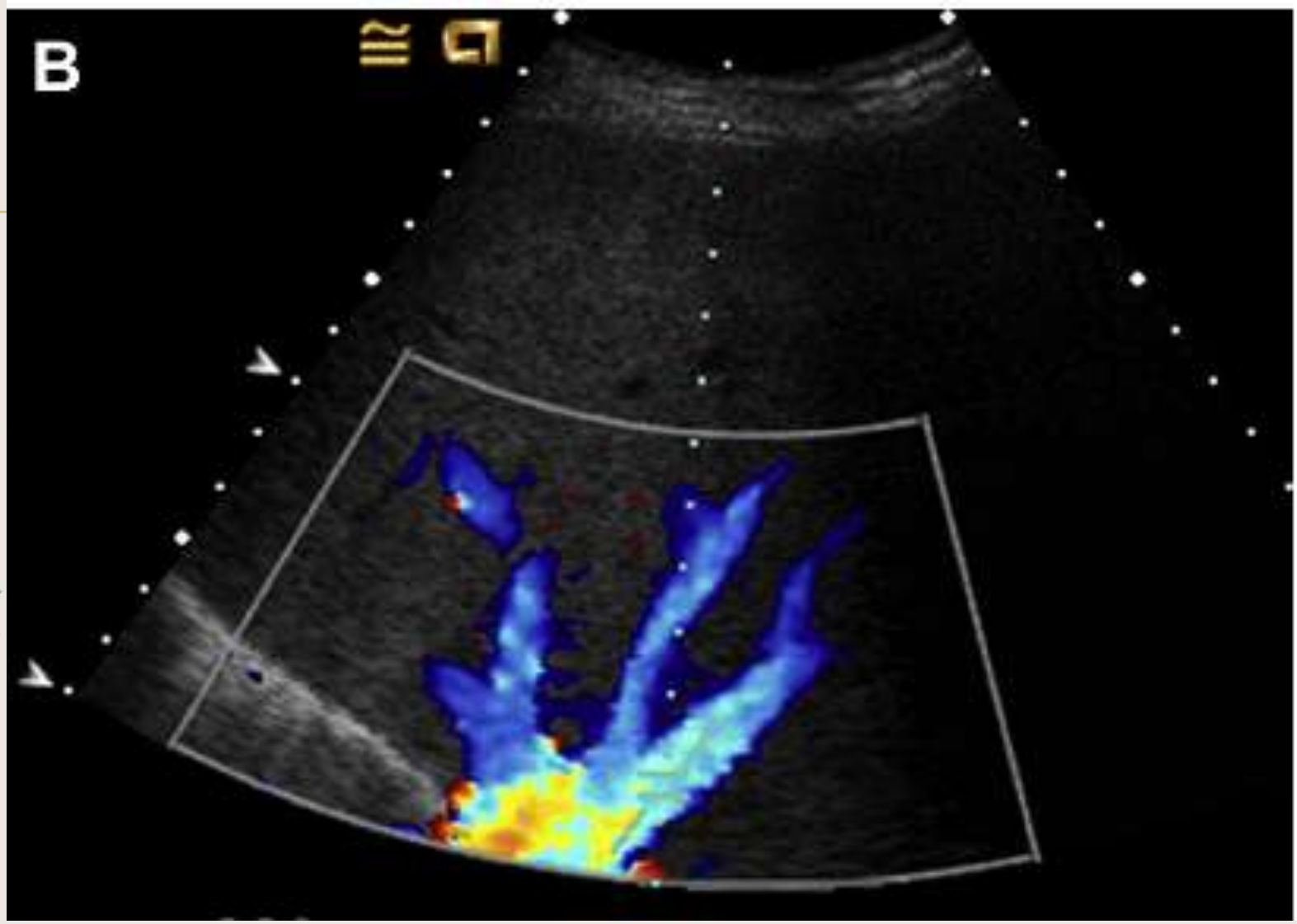
B

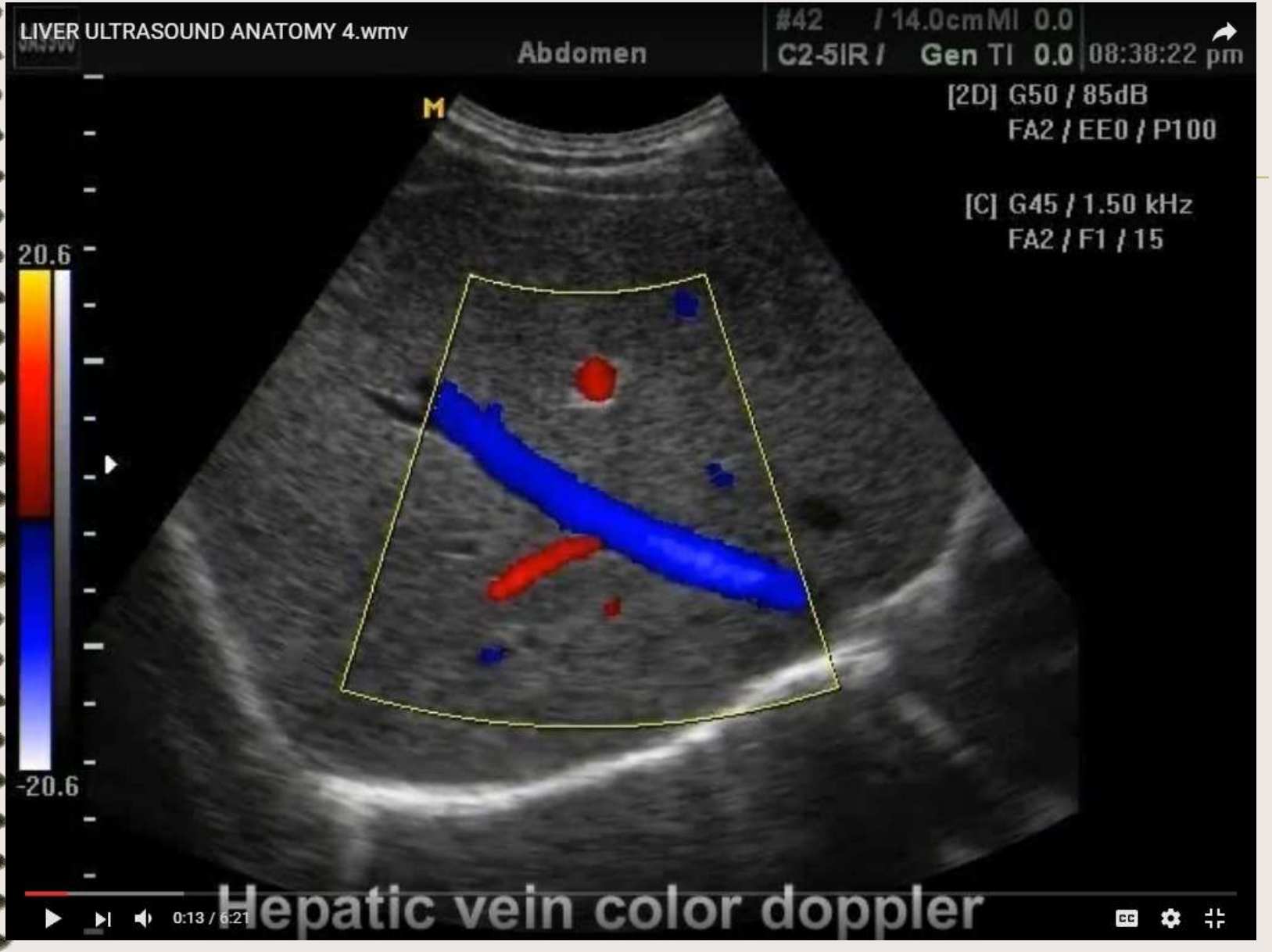
LIVER ULTRASOUND ANATOMY 4.wmv
Abdomen
#42 / 14.0cm MI 0.0
C2-5IR / Gen TI 0.0 08:38:22 pm
[2D] G50 / 85dB
FA2 / EE0 / P100
[C] G45 / 1.50 kHz
FA2 / F1 / 15
20.6
-20.6
0:13 / 6:21
Hepatic vein color doppler

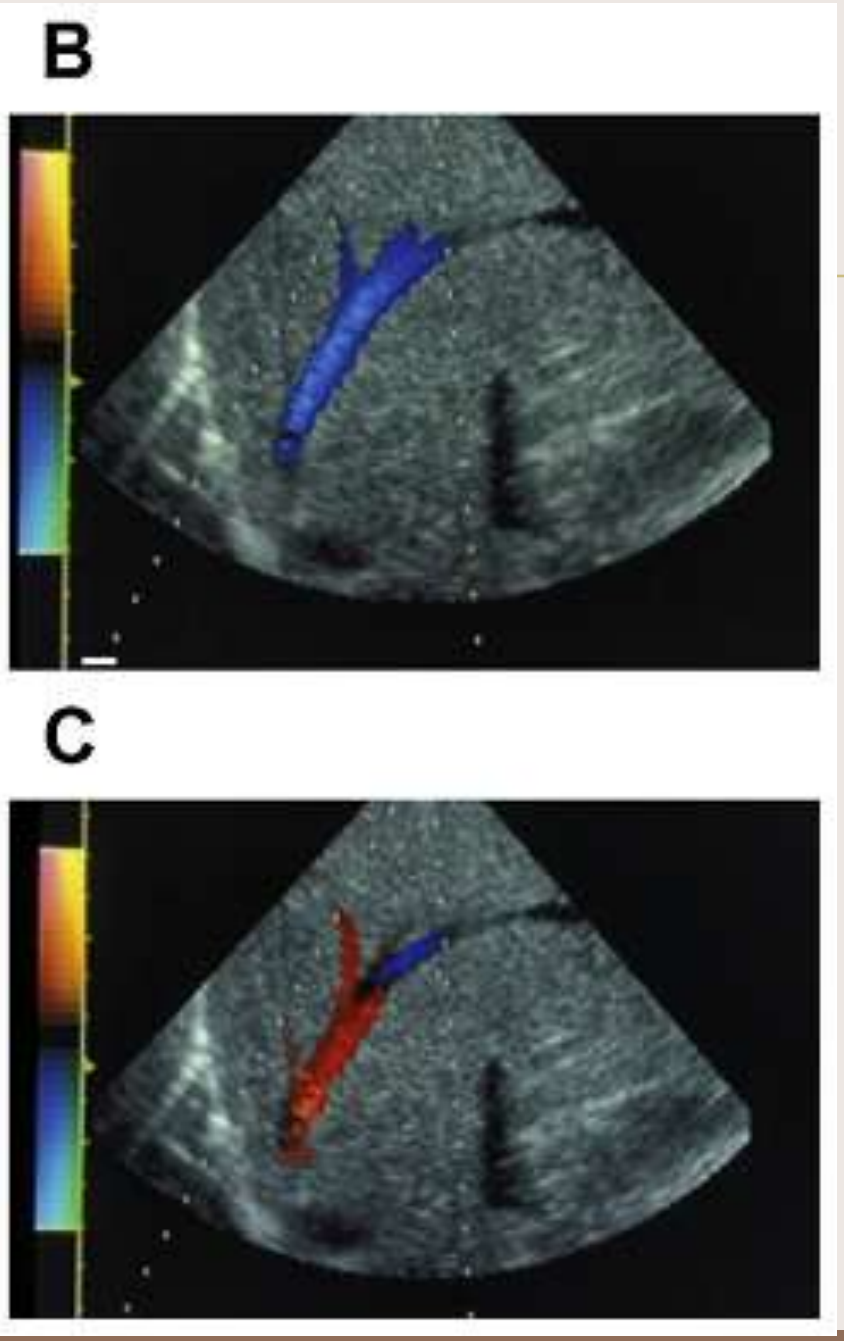

- (B) ventricular systole and
- (C) Atrial systole

showing reversal of flow.

Flow Pattern

- Antegrade flow is away from the transducer and therefore below the baseline.
- It is composed of :
- **<u>S-wave</u>**
- followed by the **<u>D-wave</u>**
- During **Atrial systole**, flow is *reversed* **(<u>A-wave</u>**).

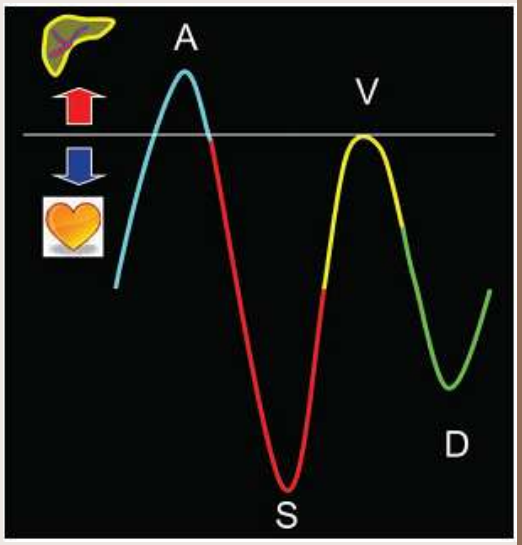

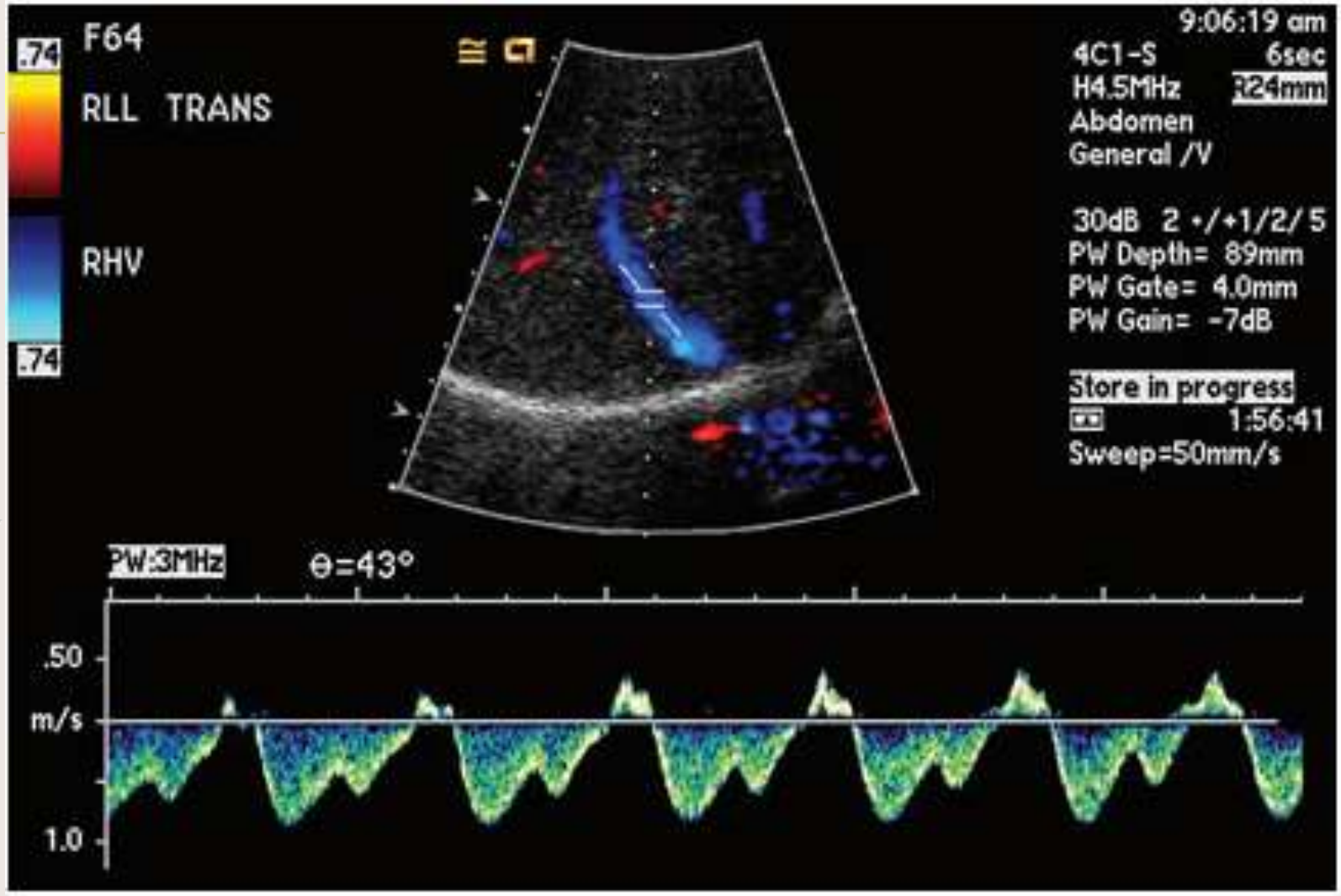
.74
F64
RLL TRANS
RHV
.74
9:06:19 am
4C1-S
6sec
H4.5MHz
Abdomen
General /V
30dB 2 +/+1/2/ 5
PW Depth= 89mm
PW Gate= 4.0mm
PW Gain= -7dB
Store in progress
1:56:41
Sweep=50mm/s
PW:3MHz
θ=43°
.50
m/s
1.0

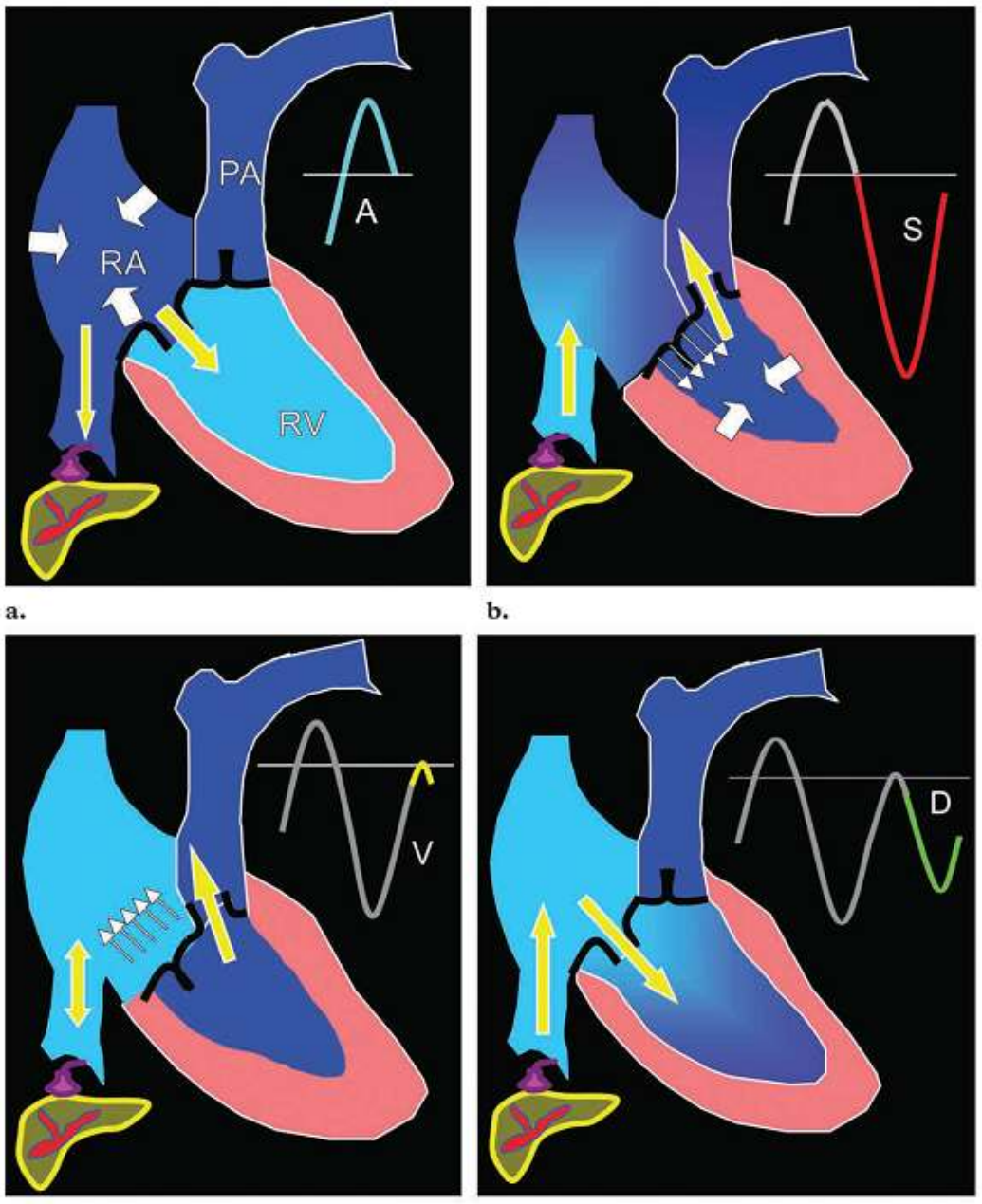
PA
A
RA
RV
a.
S
b.
V
D

Hepatic vein Doppler waveform

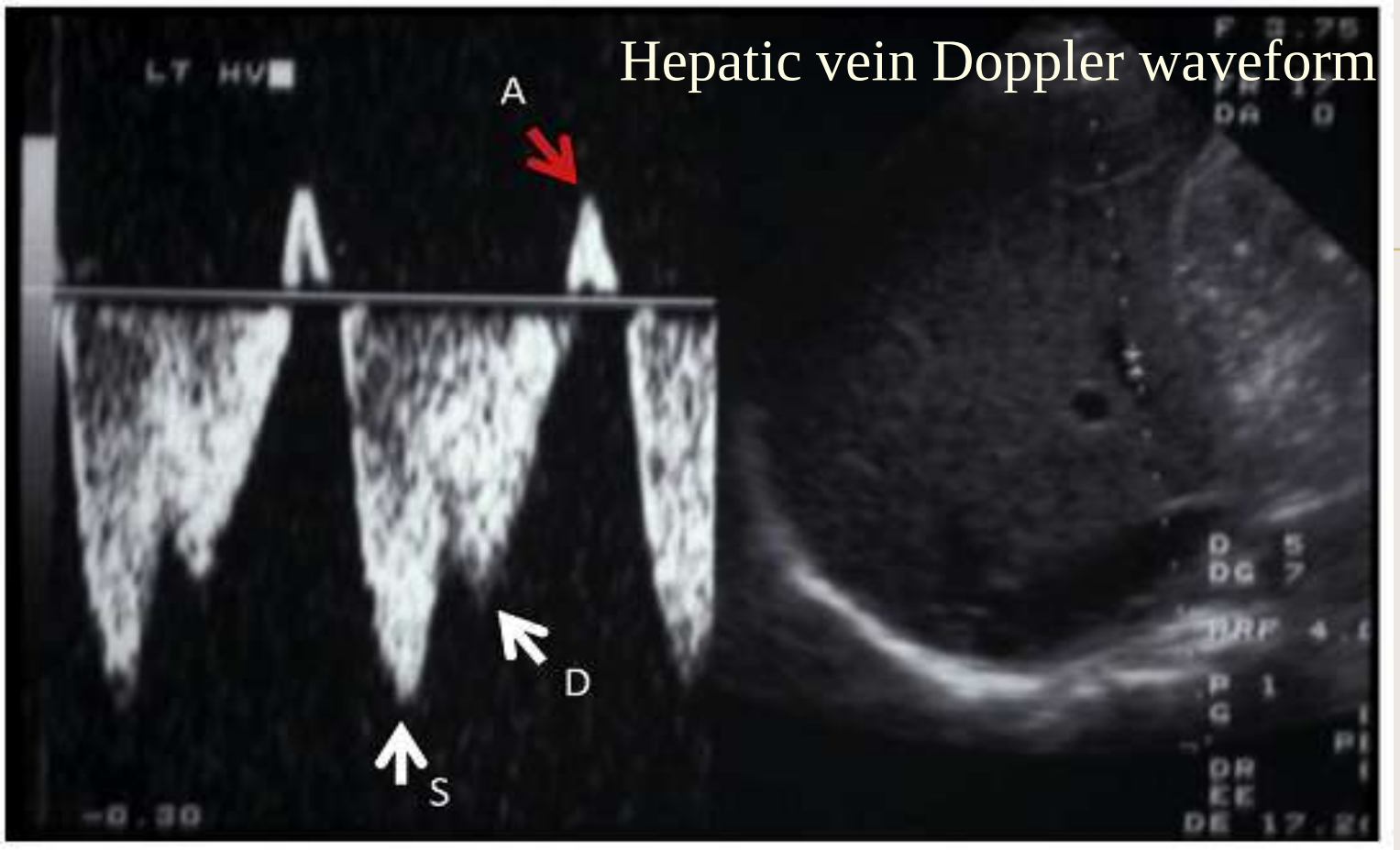

- Antegrade flow is away from the transducer and therefore below the baseline.
- It is composed of the **S-wave** followed by the **D-wave** (white arrows).
- During atrial systole, flow is reversed **(A-wave** [red arrow])

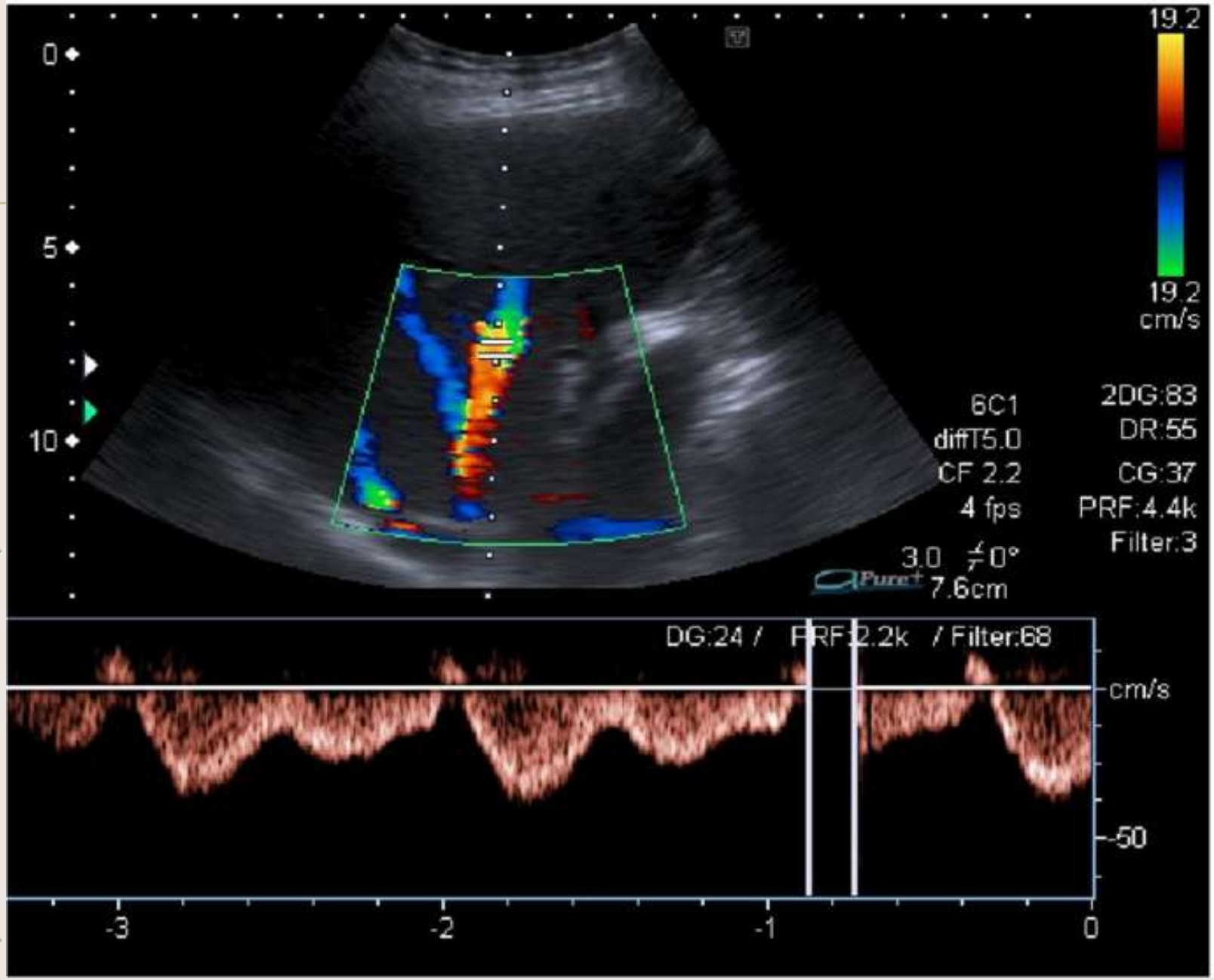
0
5
10
19.2
19.2
cm/s
6C1
diffT5.0
CF 2.2
4 fps
3.0 ∠0°
7.6cm
2DG:83
DR:55
CG:37
PRF:4.4k
Filter:3
DG:24 / PRF:2.2k / Filter:68
cm/s
-50
-3
-2
-1
0

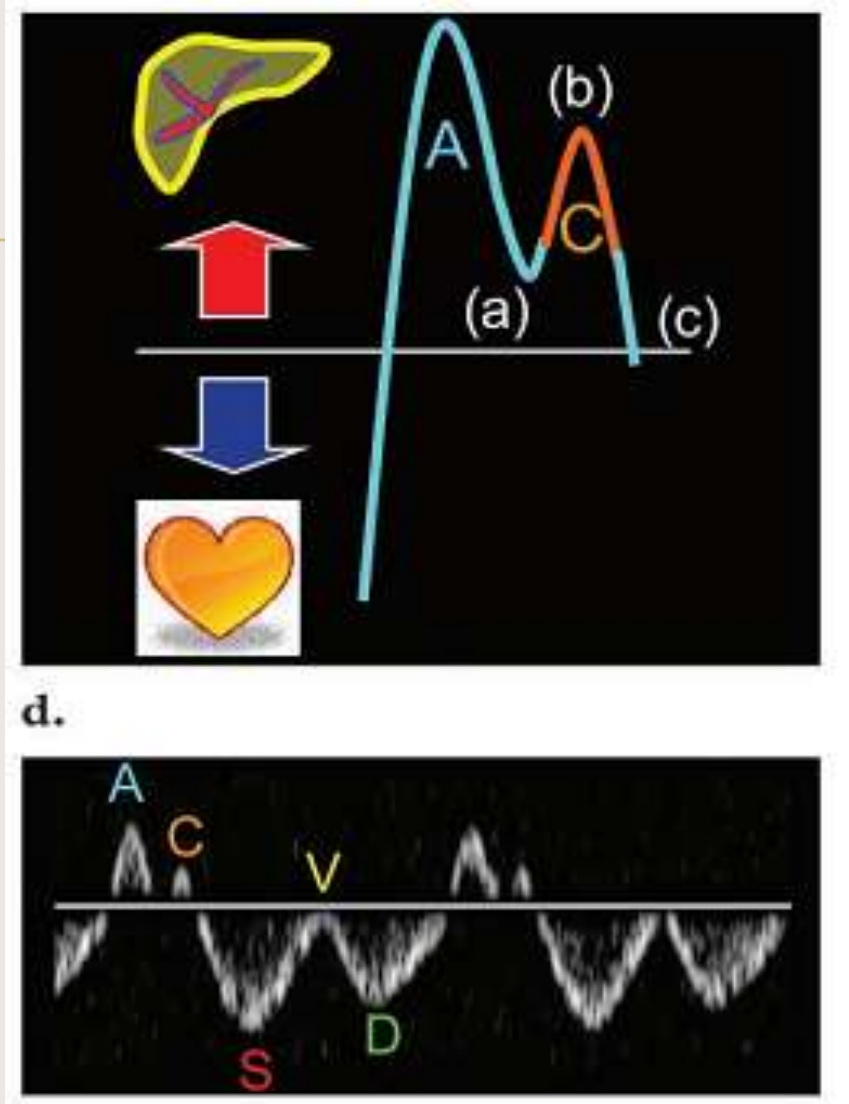

- Normal Variant C wave

Normal Variant C wave

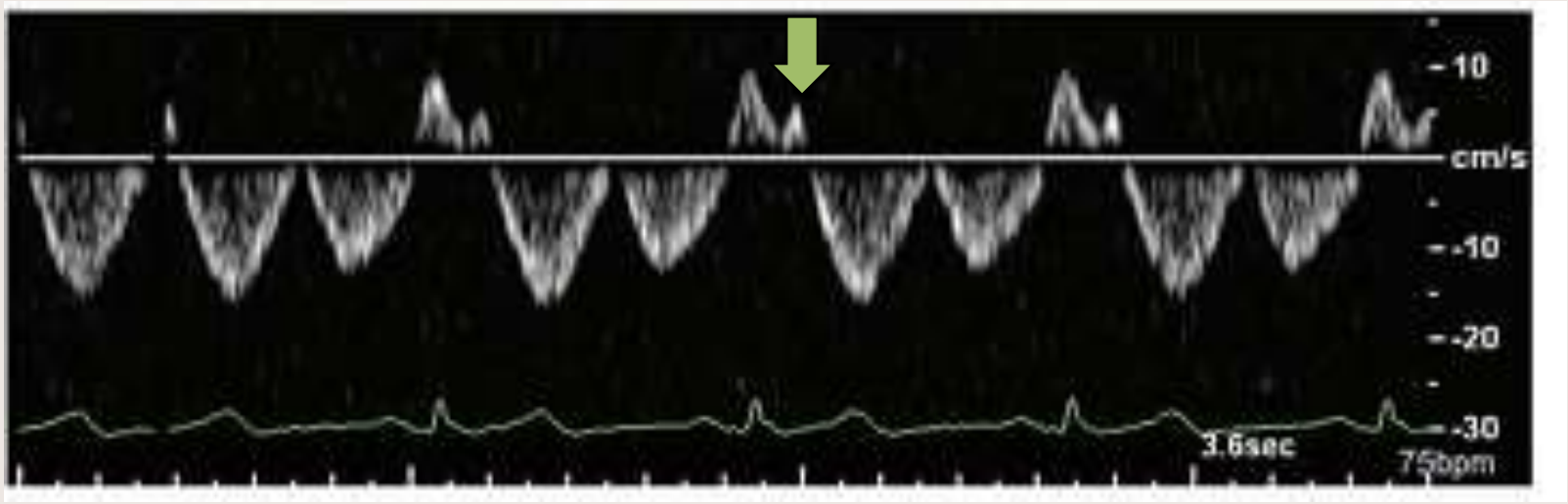

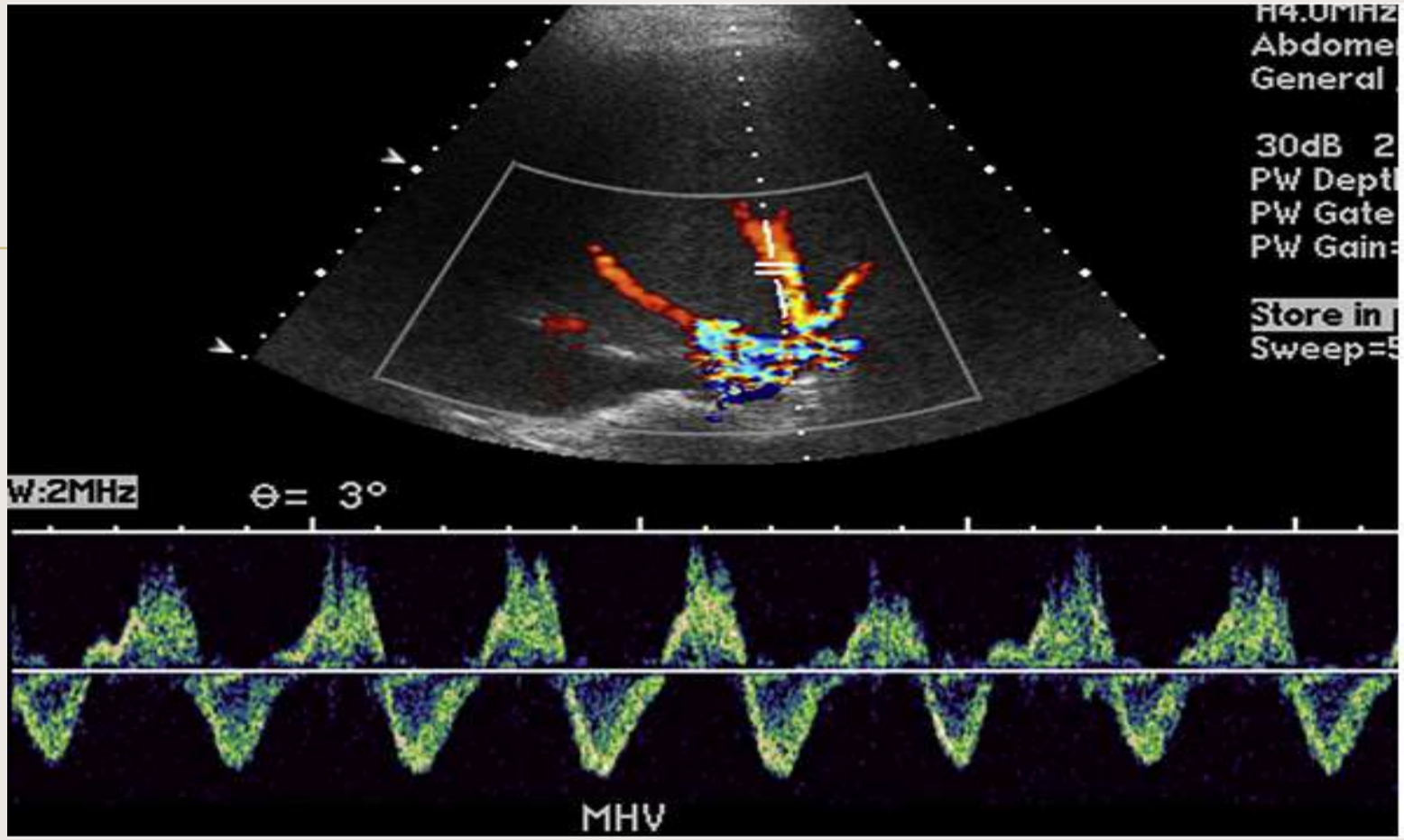

<u>Congestive cardiac failure.</u>

The Doppler spectrum shows *<u>exaggerated pulsatility</u>*,

The retrograde A-wave equal or greater than the antegrade component.

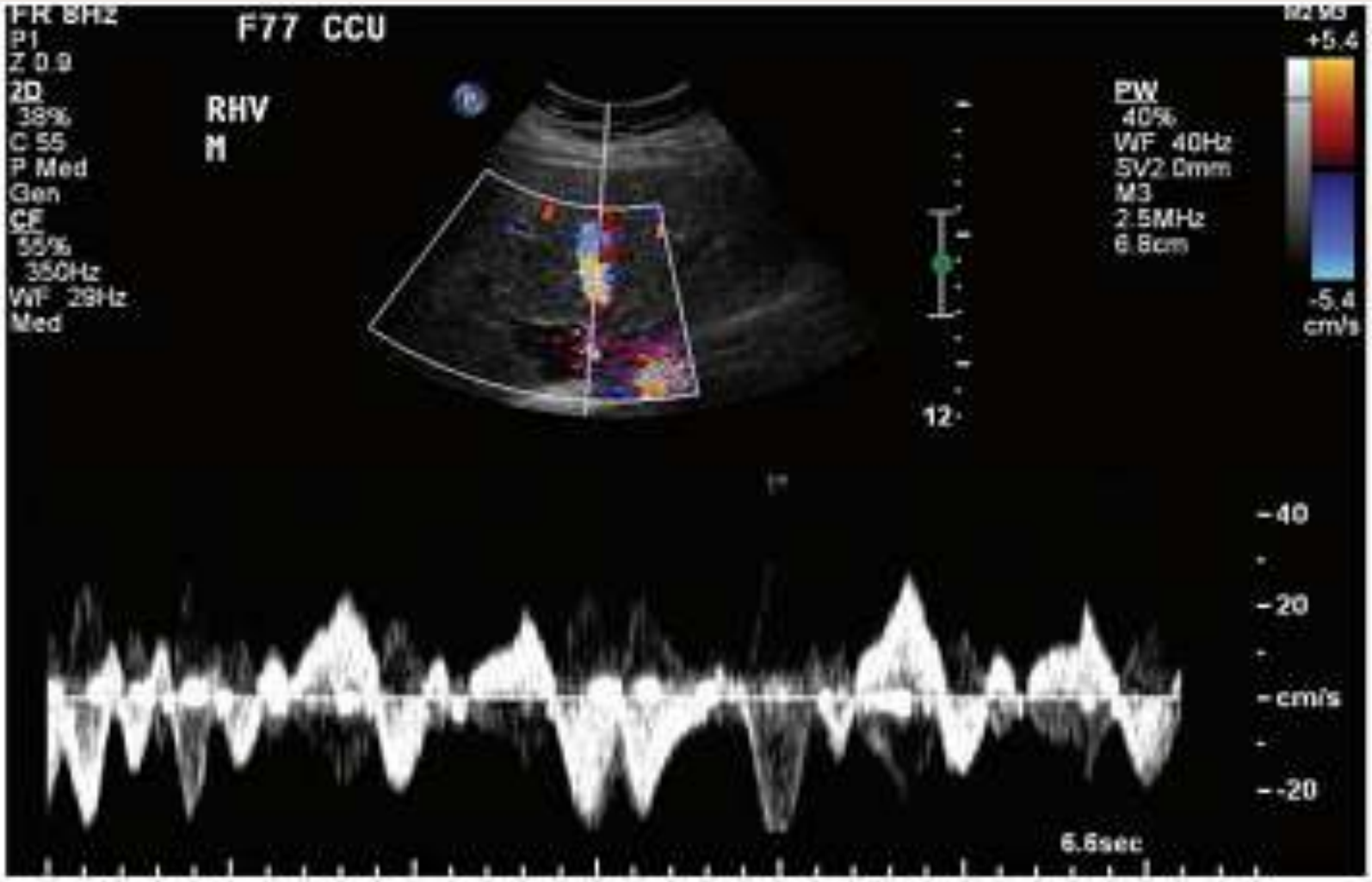

- Right hepatic vein,
- Patient with ***Atrial fibrillation***,→ shows an irregular waveform

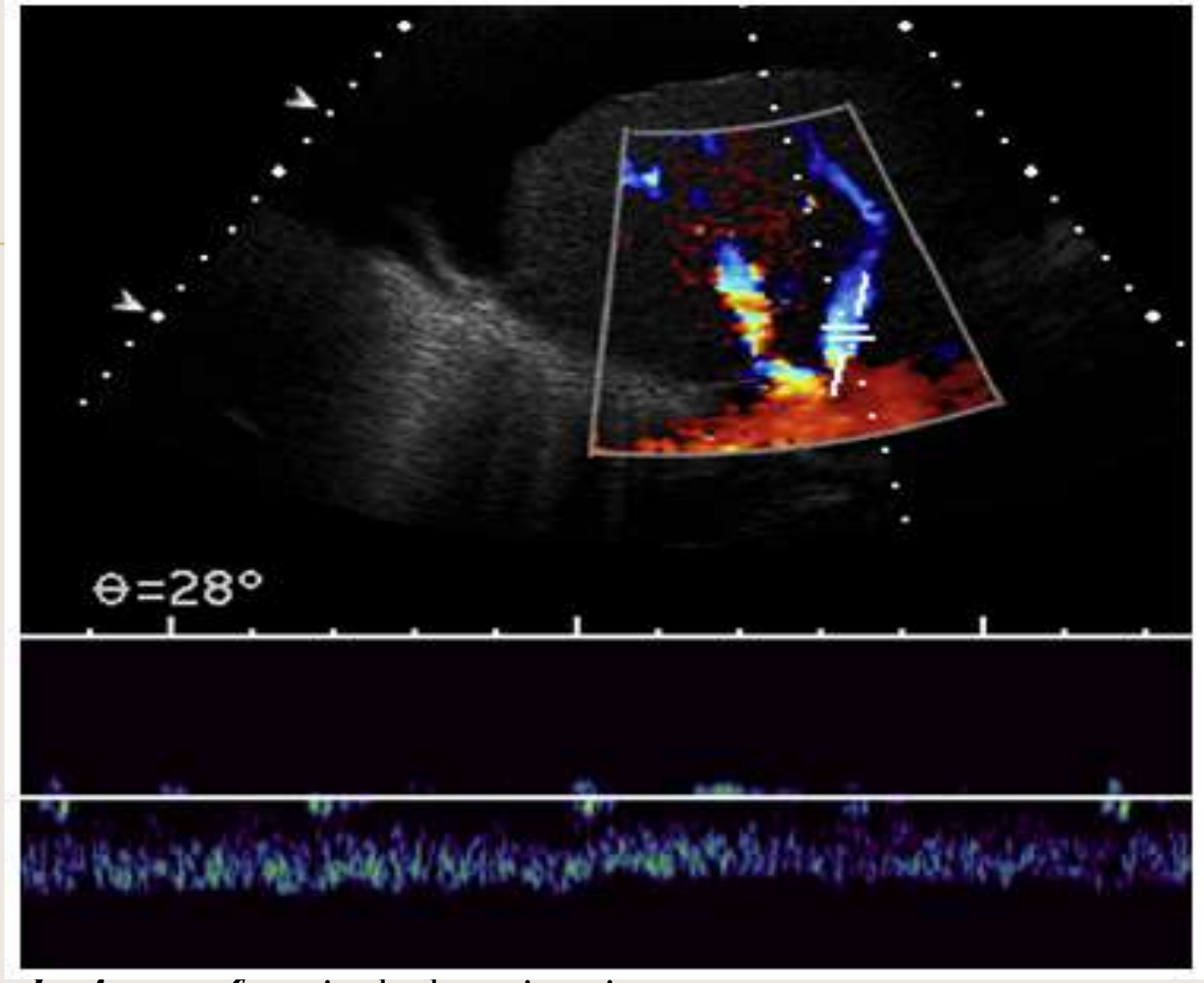

Monophasic waveform in the hepatic vein.

This can be seen in cirrhosis due to loss of liver compliance,.

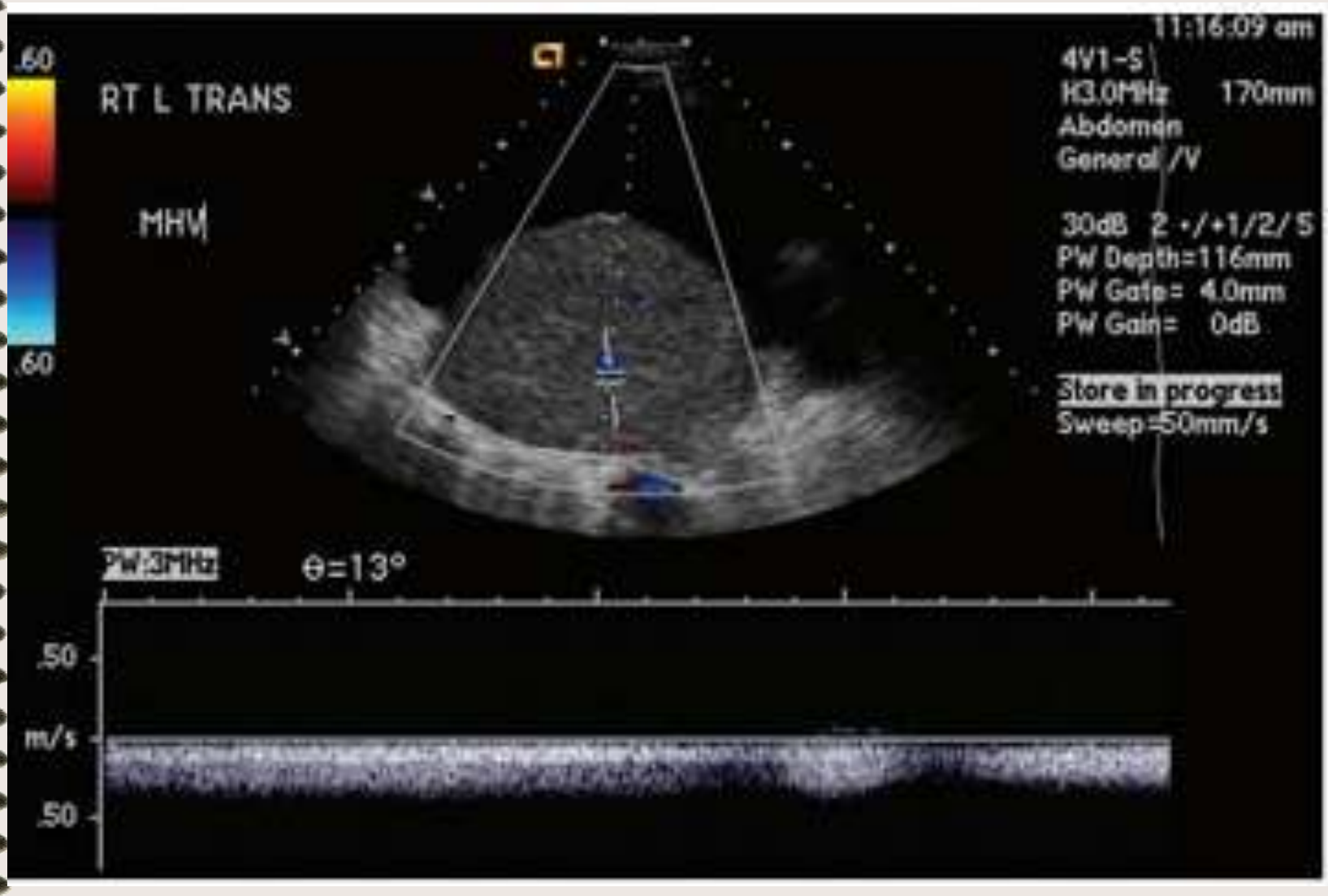
11:16:09 am
4V1-S
H3.0MHz 170mm
Abdomen
General /V
30dB 2 +/+1/2/5
PW Depth=116mm
PW Gate= 4.0mm
PW Gain= 0dB
Store in progress
Sweep=50mm/s
RT L TRANS
MHV
.60
.60
θ=13°
.50
m/s
.50

Normal + Valsalva

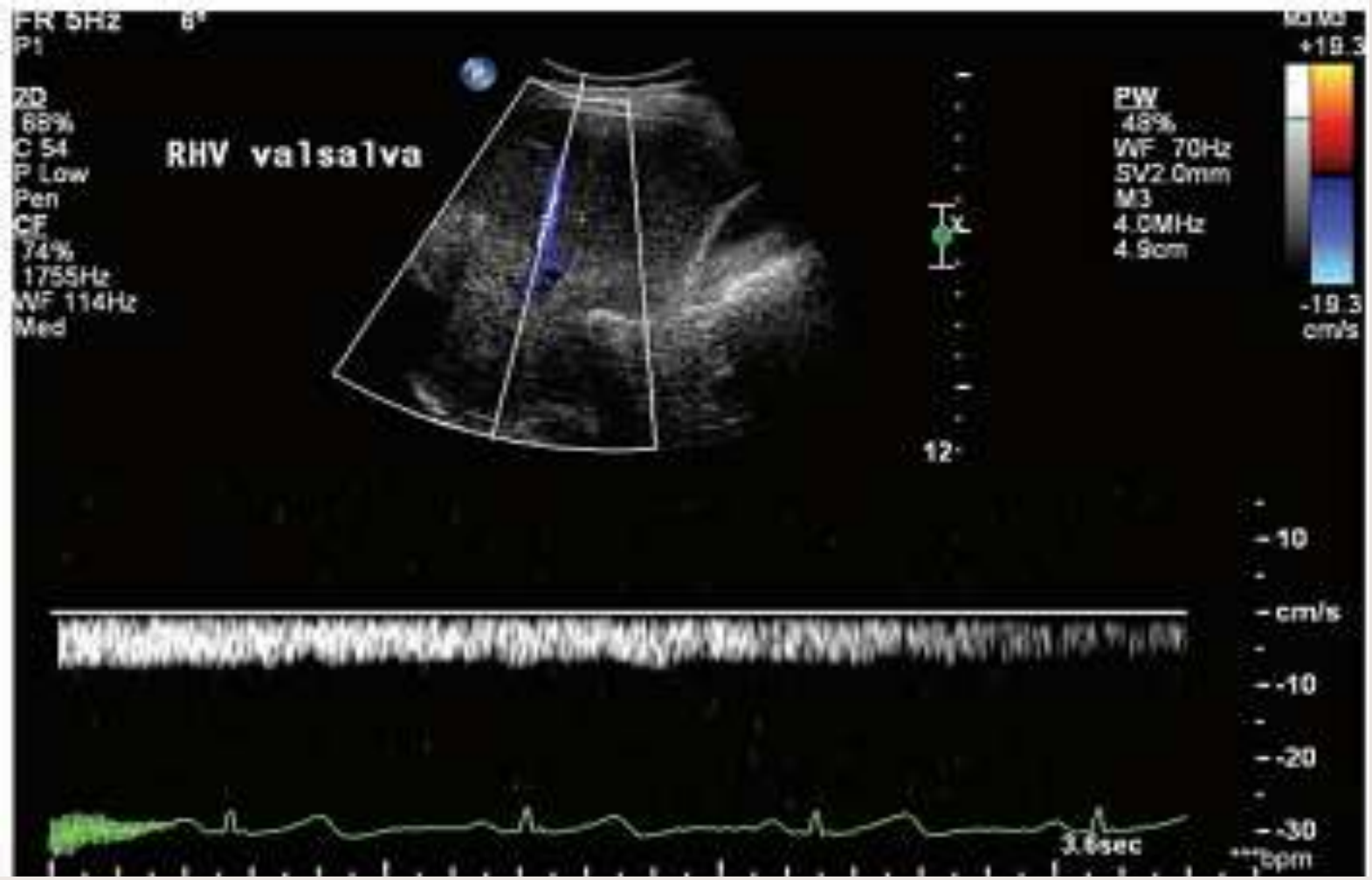

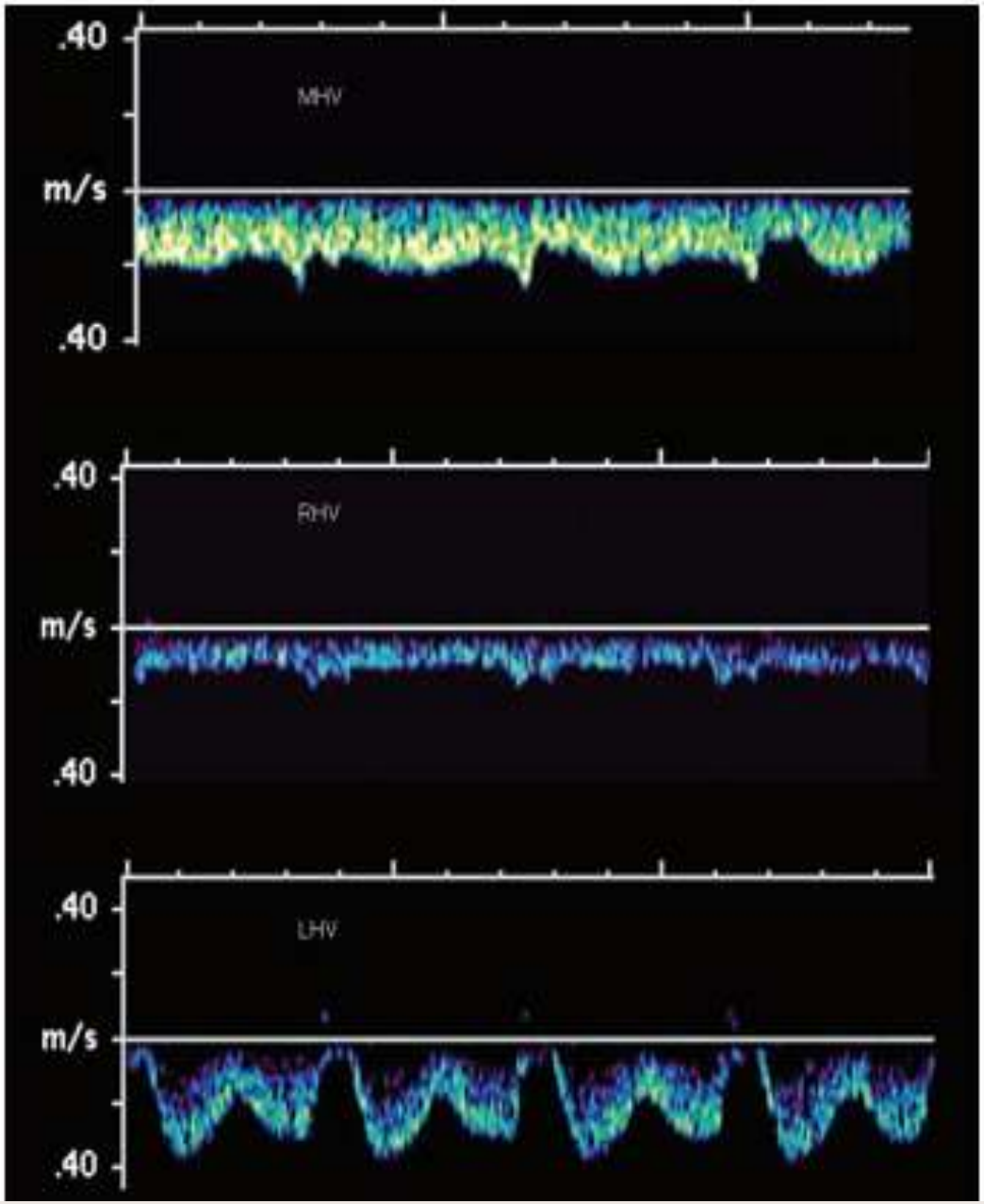

- The patient had no un-derlying liver disease;
- the presence of different patterns was due to ***technical factors.***

What is the difference?

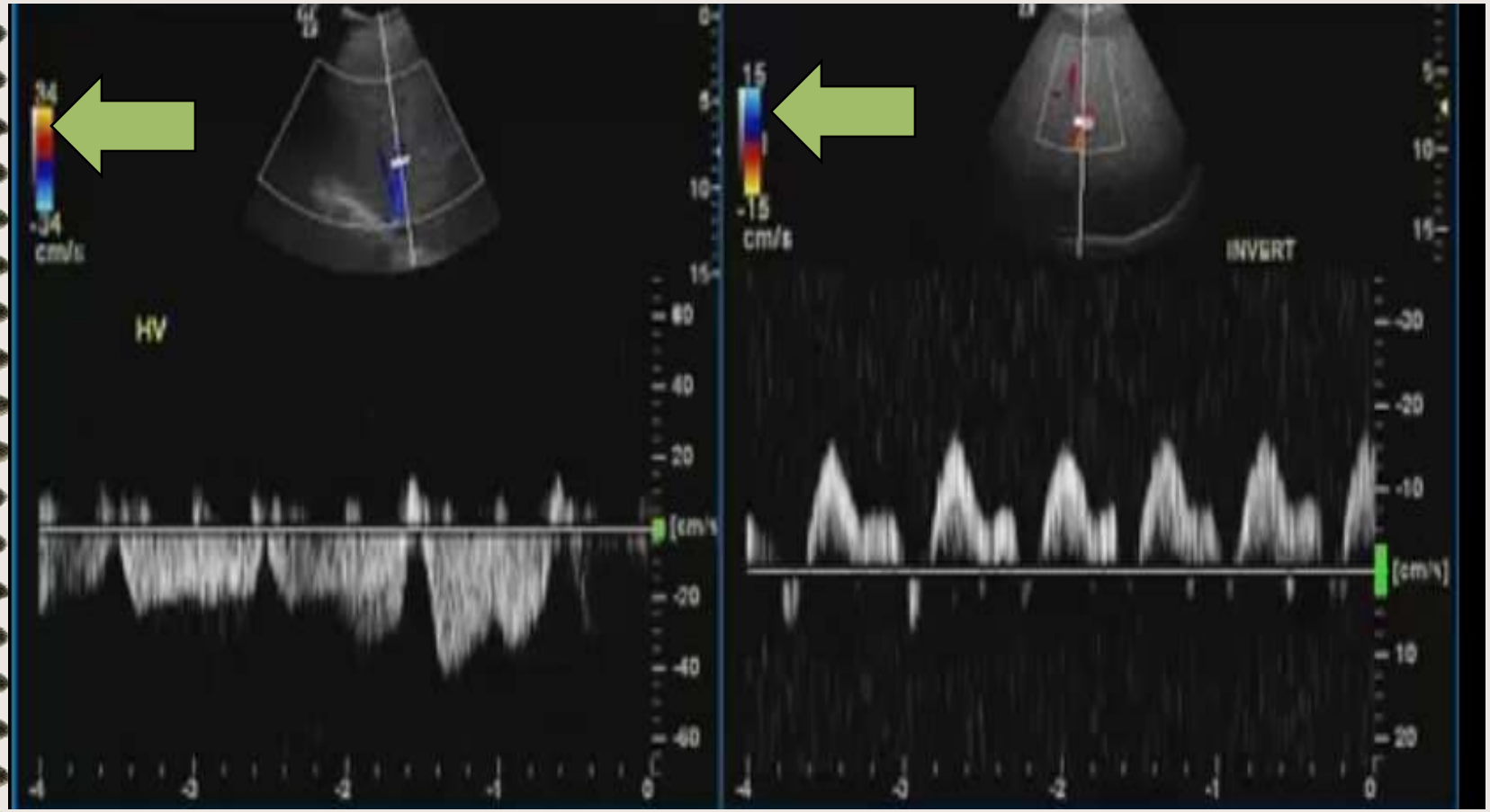

Just setting is inverted …..so be carful

3- Hepatic A. …… Facts

- Approximately 25% of the liver's blood supply comes from the proper hepatic artery
- Normal hepatic artery **resistive index** is 0.5 to 0.7
- Velocities within the hepatic artery range between 30 and 60 cm/s.

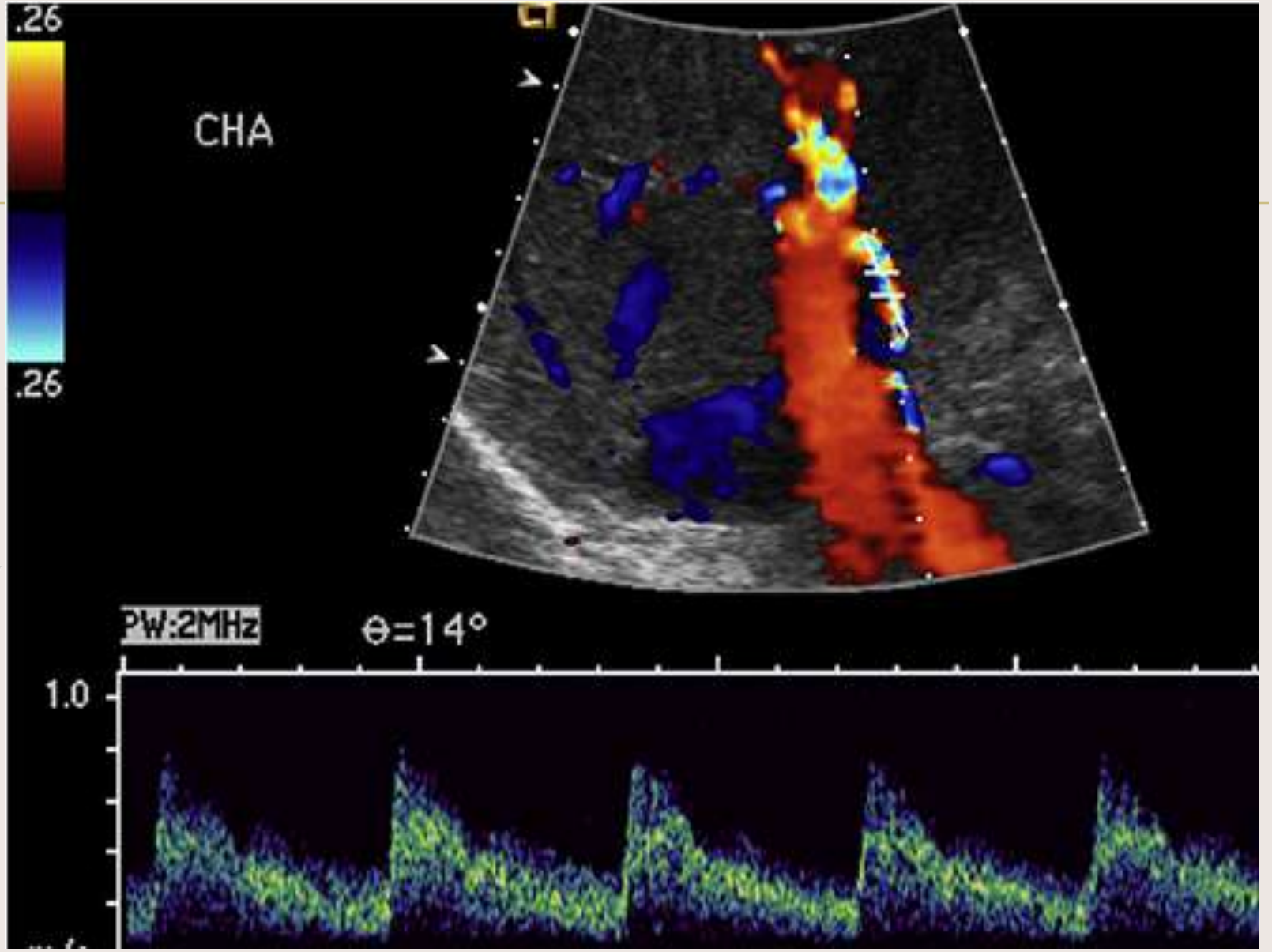

Hepatic artery – normal Biphasic low resistance flow

low-resistance artery, the trough of the waveform at end diastole is high (arrows).

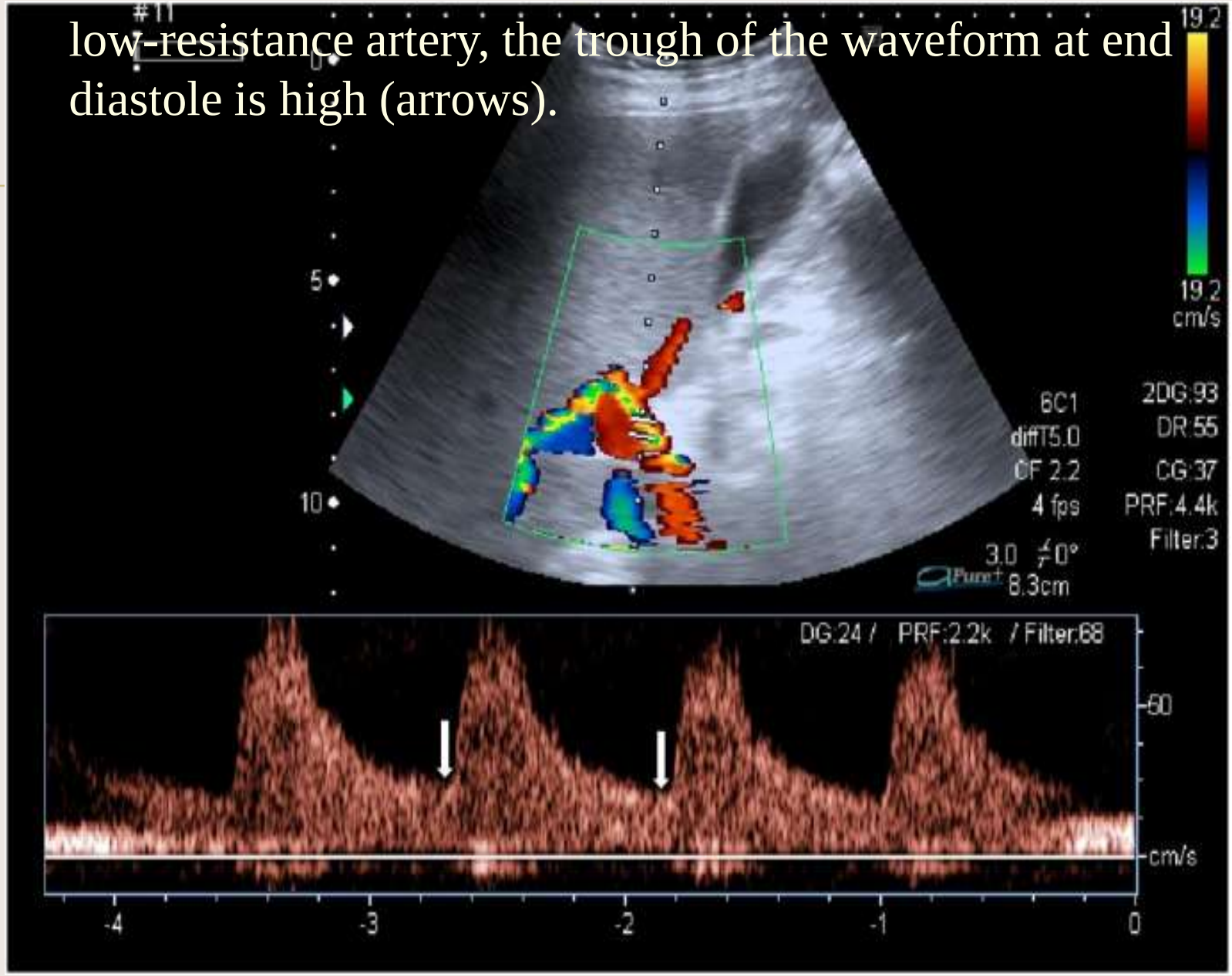

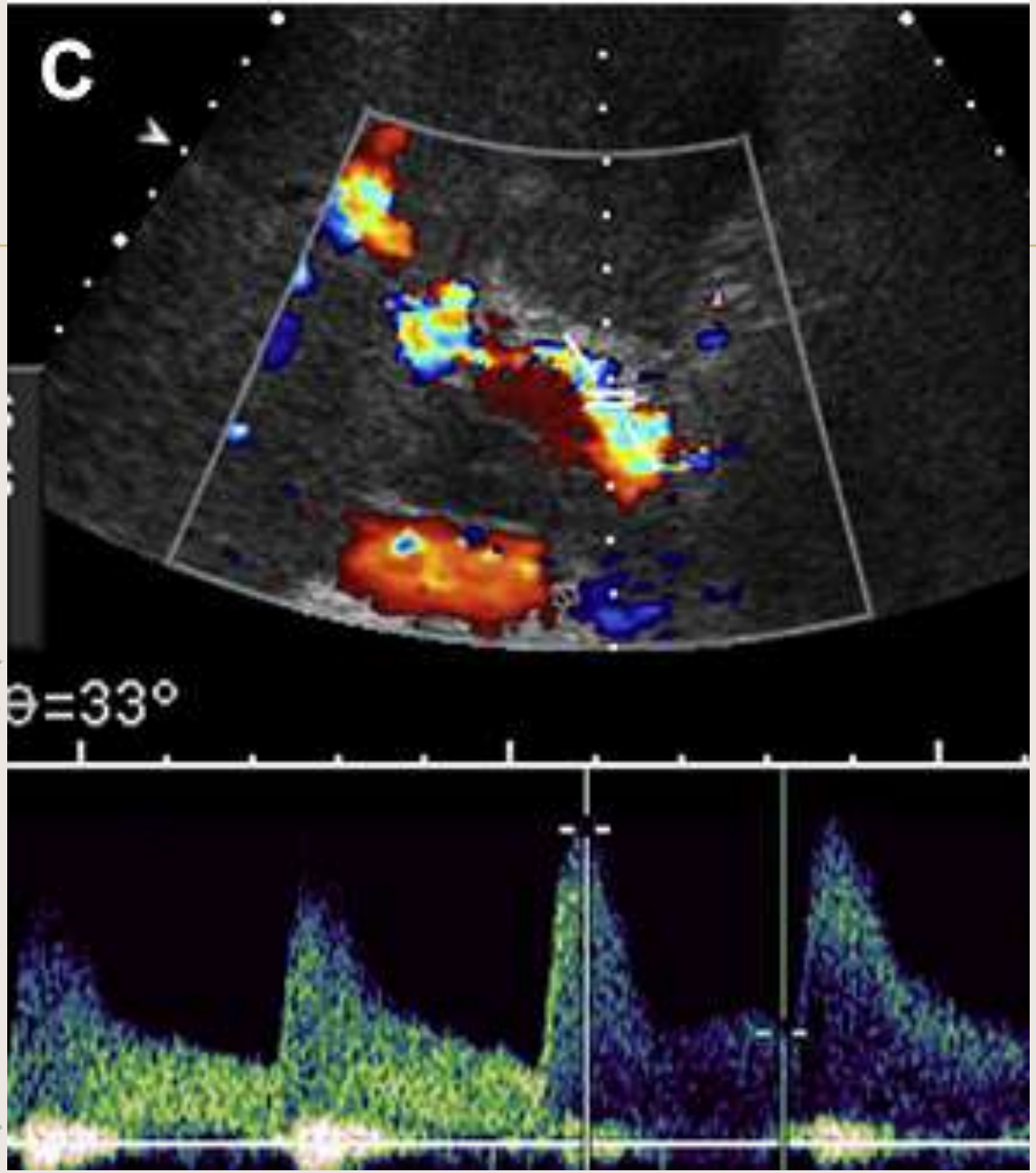

Hypertrophied hepatic artery in portal hypertension.

The hepatic artery is the multicolored vessel superficial to the portal vein (red).

Doppler spectrum confirms arterial waveform.

- High resistance waveform is ***nonspecific***,
- but can be found in
  - Advanced **cirrhosis,**
  - severe parenchymal liver disease,
  - hepatic **congestion**,
  - hepatic **venous obstruction**,
  - or diffuse **microvascular disease**
- It can also be found in :
  - **Healthy** individual postprandial or in advanced age.

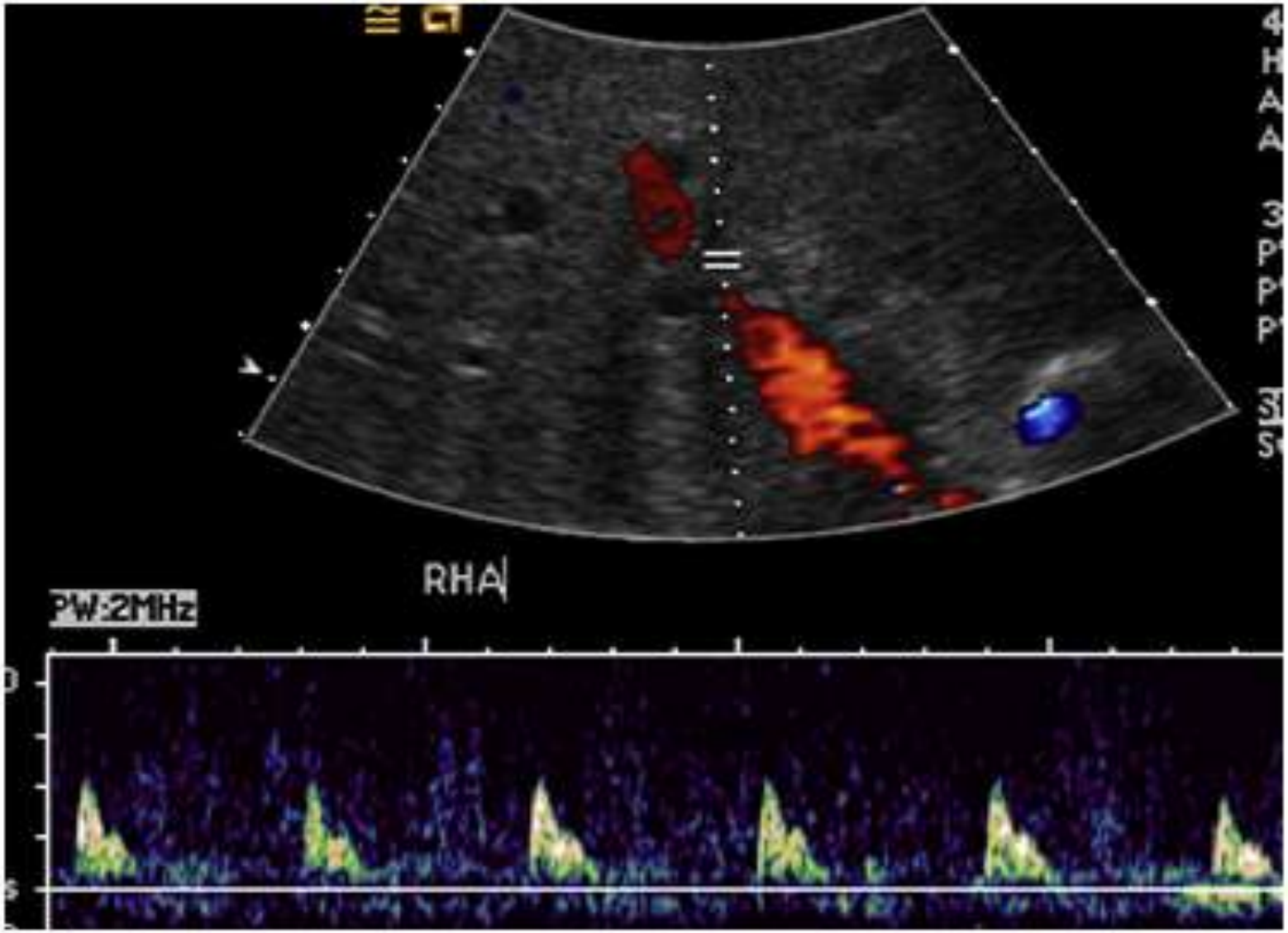

Fig. 2. Right hepatic artery showing a high-resistance waveform. There is no flow in diastole.

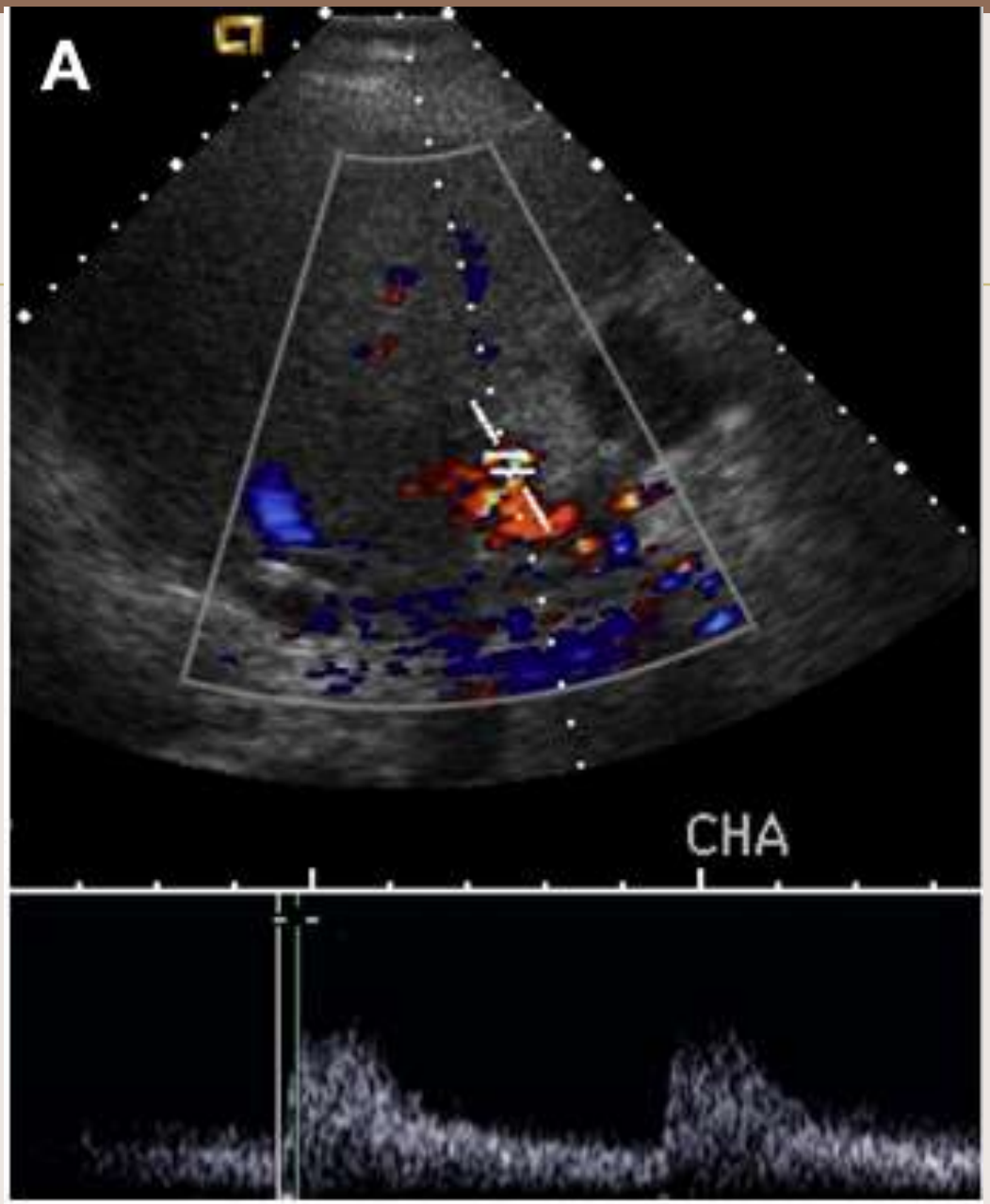

Normal common hepatic artery waveform ar


imgflip.com

Finally,, *Parameters are a lot …..*

IVC COLLAPSIBILITY INDEX

$$\text{IVCCI (\%)} = \frac{\text{Max IVC Diameter Expiration} - \text{Min IVC Diameter Inspiration}}{\text{Max IVC Diameter Expiration}} \times 100$$

MAXIMAL IVC DIAMETER (CM) ADULT PATIENT	RESPIRATORY CHANGE IN IVC DIAMETER (%)	APPROXIMATE CVP
≤ 1.2	TOTAL COLLAPSE	LOW (INTRAVASCULAR VOLUME DEPLETION
< 1.3 - 1.6	> 50%	2 - 5 (NORMAL)
1.7 - 2.5	> 50%	6 - 10 (SLIGHT ELEVATION)
1.5 - 2.5	> 50%	10 - 15 (MODERATE INCREASE)
> 2.5	> 50%	15 - 20 (MARKEDLY INCREASED)
> 25	NO CHANGE	> 20 (FLUID OVERLOAD)

Summary

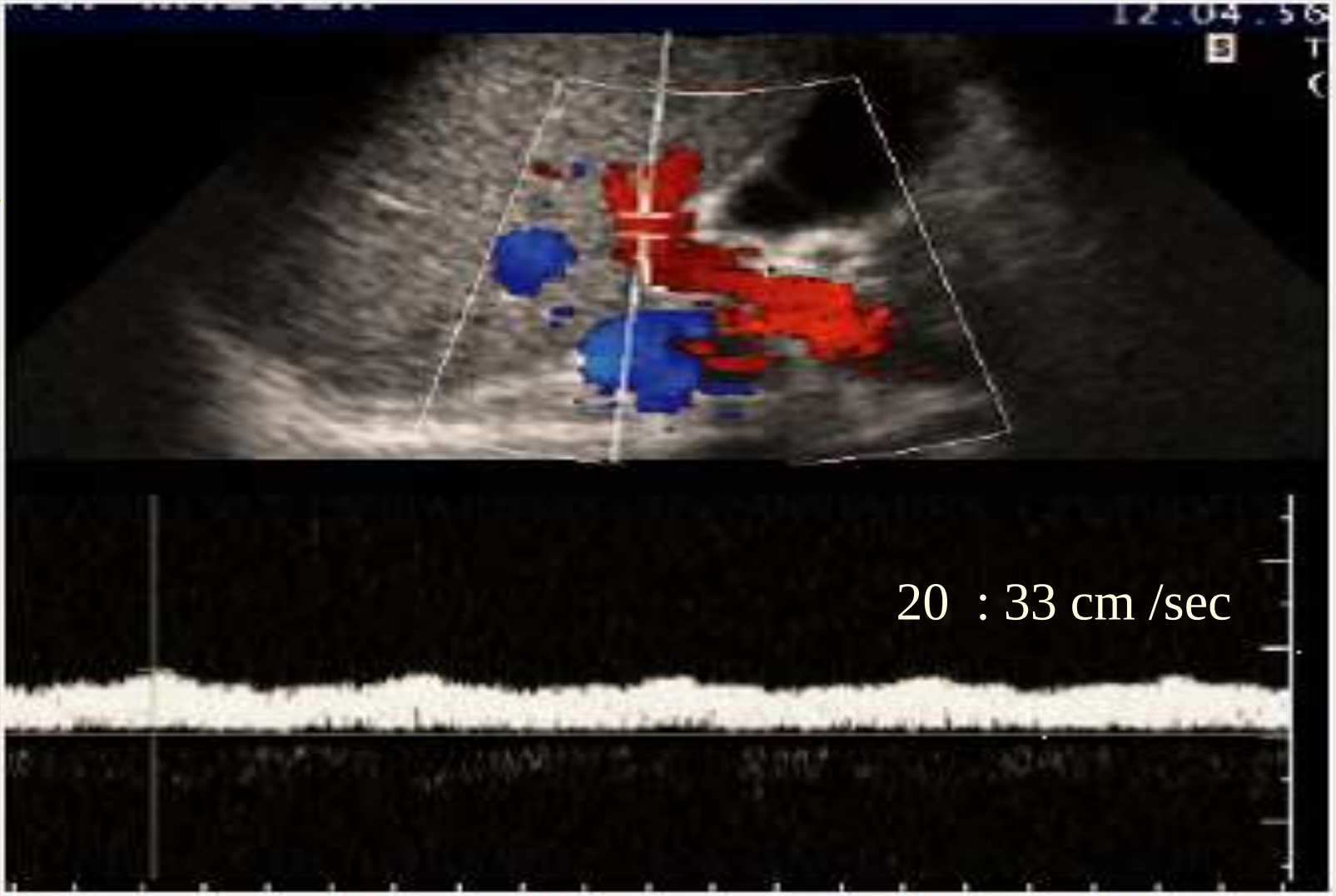

Figure 2.26 Normal portal vein waveform. Respiratory modulations are evident.

Normal hepatic vein waveform – 3 components

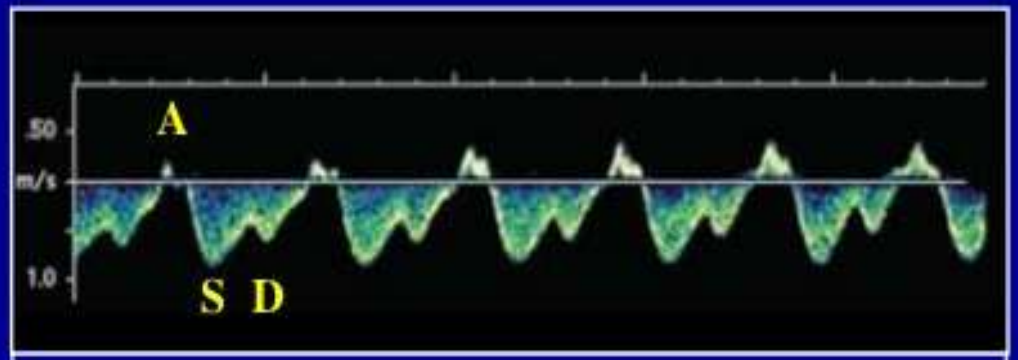

A	Atrial systole
S	Ventricular systole
D	Atrial diastole

S wave > D wave

Commonly described as triphasic

Kruskal JB et al. RadioGraphics 2004 ; 24 : 657 – 675.

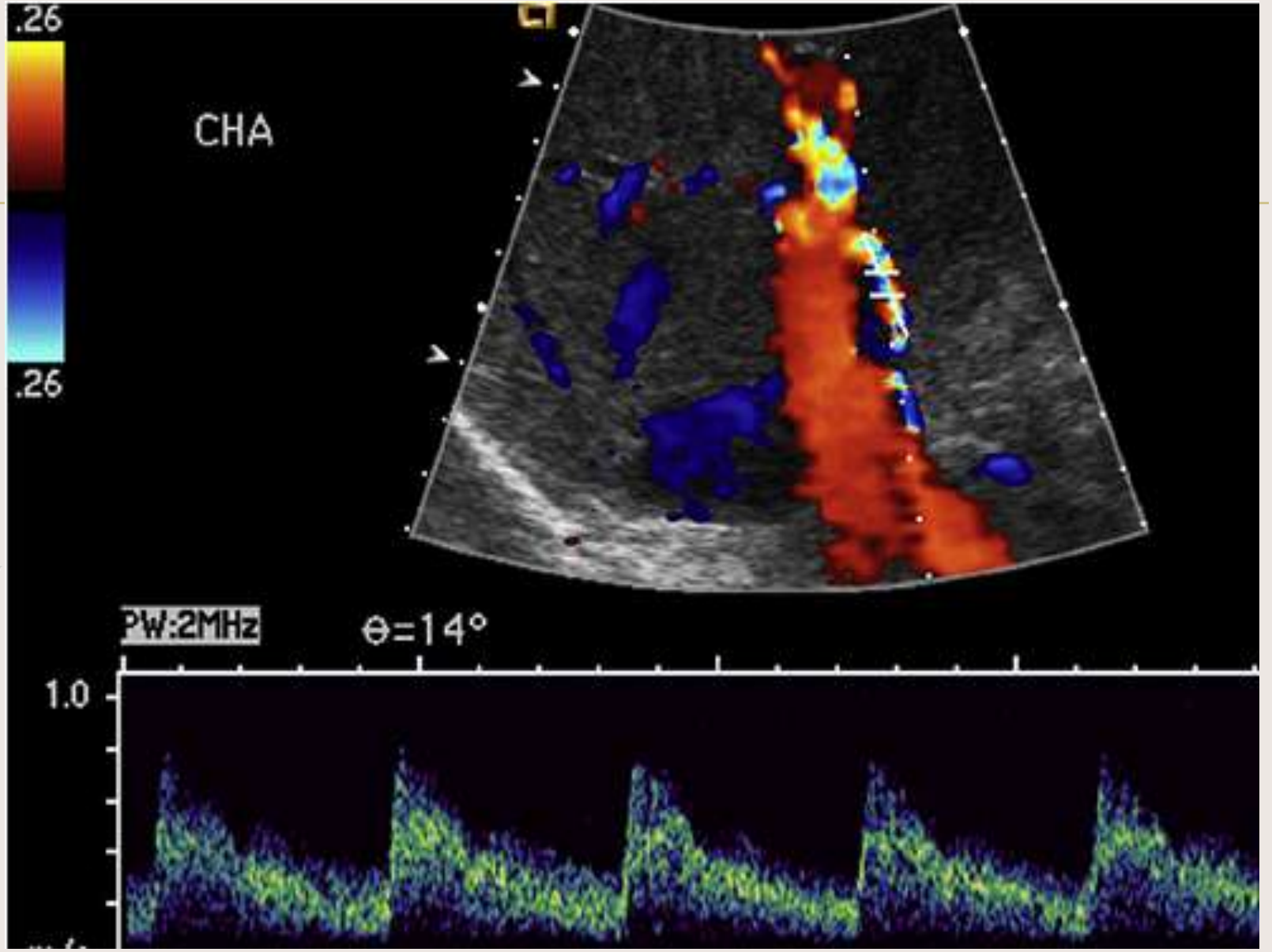

Hepatic artery – normal Biphasic low resistance flow

PORTAL HYPERTENSION

THE FLORIDA STATE UNIVERSITY
COLLEGE OF MEDICINE

PORTAL

PORTOSYSTEMIC ANASTOMOSIS

SYSTEMIC & CAVAL

PRESSURE

ESOPHAGEAL VARICES

DRK BLACK, TARRY STOOL

BREAKDOWN OF RED BLOOD CELLS

POTENTIALLY LETHAL

ANORECTAL VARICES

HEMORRHOIDS

SUPERIOR RECTAL VEIN

MIDDLE RECTAL VEIN

INFERIOR RECTAL VEIN

SURGICAL REPAIR

PORTAL VEIN TO IVC

SPLENIC VEIN TO RENAL VEIN

CAPUT MEDUSAE

"MEDUSA'S HEAD"

RECANALIZATION

FETAL DEVELOPMENT

BLOOD PRESSURE

PORTAL PRESSURE

CAVAL PRESSURE

VARICES

TRANSJUGULAR INTRAHEPATIC PORTOSYSTEMIC SHUNTING

TIPS

Sources

- https://www.youtube.com/watch?v=78MmyYJK8bQ
- https://www.youtube.com/watch?v=RfQveRQJXJ4

Ultrasound in Portal Hypertension

- https://www.youtube.com/watch?v=Cox6Z5pqMBo

Portal Hypertension: Animated Review

- https://www.youtube.com/watch?v=dkO3DlHlFCc&index=9&list=PLF8XZxHGFioE3k4E7EkL_gu4EL2SpIF3y

Duplex of portal vein - Dr Hatem Elazizi (In Arabic)

- *Doppler Ultrasound of the Liver, Portal Hypertension, and Transjugular Intrahepatic Portosystemic Shunts - Melissa Davis,MD, Wui K. Chong, MBBS, FRCR**

- *Understanding the Spectral Doppler Waveform of the Hepatic Veins in Health and Disease. "Meir H. Scheinfeld et al. "*
- *Doppler Ultrasonography of the Liver: What Every General Radiologist Should Know "T. González de la Huebra Labrador et al."*

For More Topics

Visit

http://students-of-prof-mamdouh-mahfouz.blogspot.com

Or

Face Book Group " Prof. Mamdouh Mahfouz Students"

https://www.facebook.com/groups/1789265188215 45/

WITH My Best Wishes

Ahmad Mokhtar Abodahab

26 Nov 2016

نسألكم الدعاء

صدقة جارية

لروح اخى المهندس / حاتم أبودهب